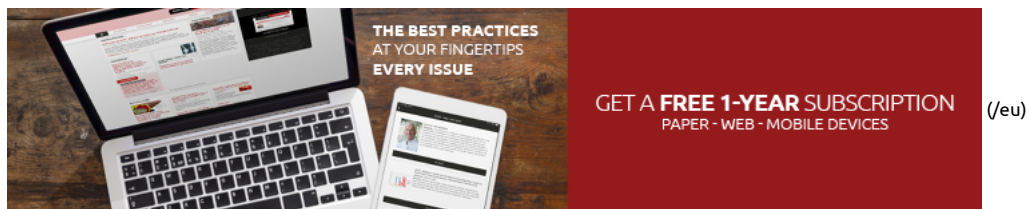


FR (<http://www.maitrise-orthopedique.com>) EN

Frédéric Laud



## Search

Follow us on social media: [f](#) [t](#) [i](#)

Published in ▶ N°001 - May / June 2019 (<https://mo-journal.com/journals/view/n001-may-june-2019-49>)  
Article viewed 46 times

## Is there still any place for femoral osteotomy in conservative hip surgery?

By Frédéric Laude, Alice Nlandu, Roxana Viamont-Guerra in category TECHNIQUE  
*Clinique du sport, 36 boulevard saint Marcel, 75005 Paris - France*

In recent years there has been quite a marked revival in the popularity of hip salvage surgery. The concept of femoroacetabular impingement, as developed at length by Rheinold Ganz, has shed light on one of the major causes of osteoarthritis of the hip and made it possible to offer early treatment.

### Introduction

In recent years there has been quite a marked revival in the popularity of hip salvage surgery. The concept of femoroacetabular impingement, as developed at length by Rheinold Ganz, has shed light on one of the major causes of osteoarthritis of the hip and made it possible to offer early treatment. Specifically, Ganz designed a technique involving an open approach with anterior surgical dislocation of the hip and trochanteric osteotomy,[1] which in turn has resulted in the proposal of a number of methods such as femoral head sphericalization and labral repair, with or without acetabuloplasty. Even though this surgery was initially developed as an open technique under the influence of its inventor, it is now routinely performed arthroscopically.

The concept of hip instability with or without acetabular dysplasia[3] has been around for several years, resulting in the proposal of certain original techniques that go beyond the 'quasi-traditional' periacetabular osteotomy, such as capsuloplasty.

**f** A common procedure some fifty years ago, it is hardly ever taught to new surgeons nowadays despite being the best osteotomy for correcting proximal femoral deformities.

**t** Instead, hip replacement surgery has taken over and relegated it into oblivion. A firm favourite among older surgeons, who still uses the MacMurray procedure,[4] and has anyone new even read the works of Bombelli?[5, 6] Femoral osteotomy is only ever really performed in a paediatric setting where replacement surgery is not the first-line approach.

**i** In addition, the procedure poses a certain number of recovery issues which are liked by no-one, especially the patients. It is a very hard procedure to sell. The proximal femur takes a long time to heal. The resulting scarring is fairly extensive, and nearly every case will require removal of the material.

Femoral osteotomy also gained a reputation for altering the shape of the femoral medullary cavity and thus compromising any future hip replacement.[7,8]

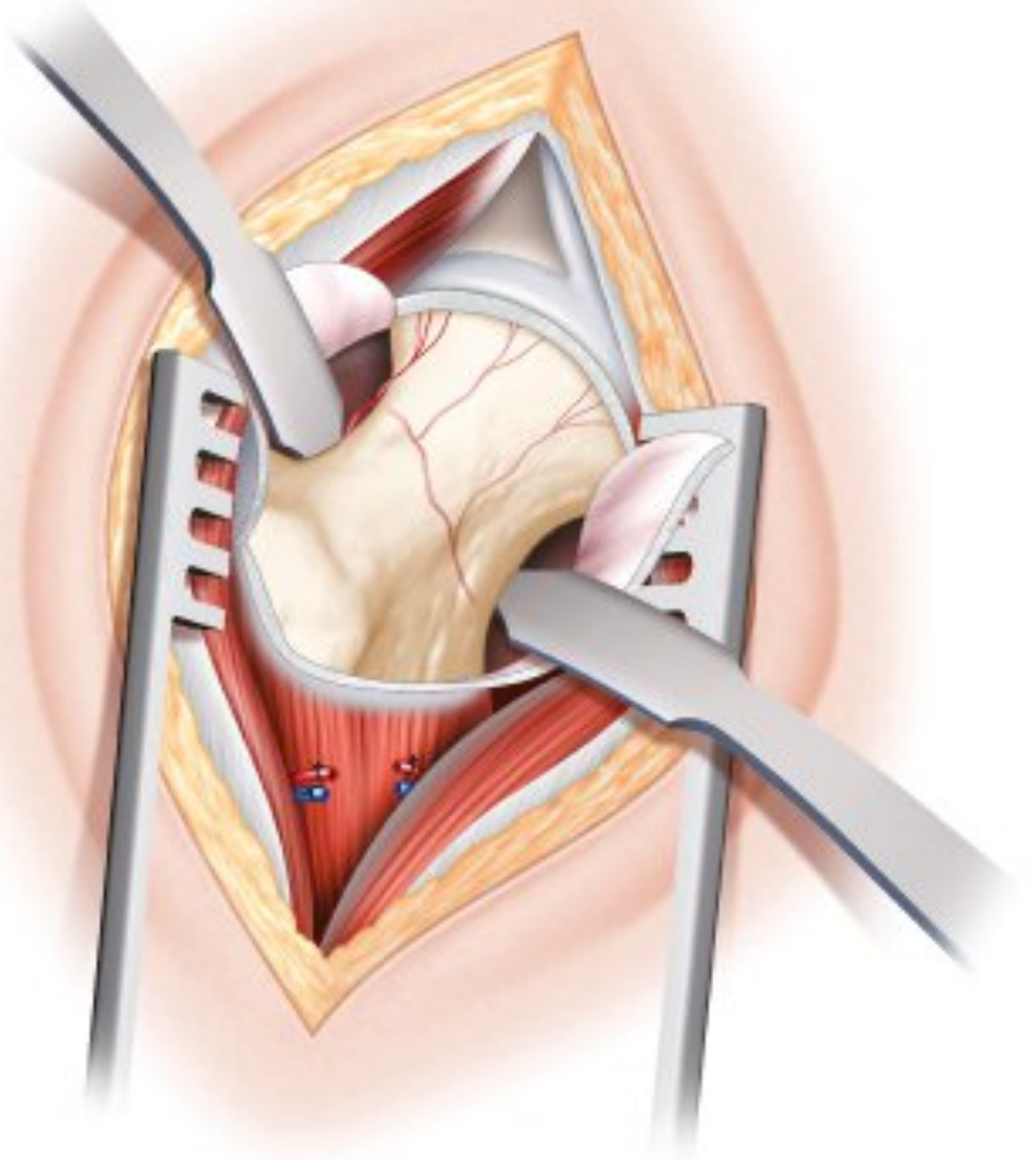
However, if the surgeon is particularly keen on salvage surgery, there is sometimes no option other than to correct the femur in order to resolve an architectural defect. Osteotomy is therefore a procedure that, in the hands of a specialist, is still highly relevant within the therapeutic arsenal of salvage surgery.[5, 9, 10]

### The traditional surgical approach

Osteotomies are traditionally performed via a lateral portal passing through the fascia lata down to the lateral aspect of the greater trochanter and the proximal vastus lateralis muscle. Vastus lateralis is detached from its insertion onto the greater trochanter. The osteotomy line tends to be more or less horizontal, usually passing between the lower part of the greater trochanter and terminating above the lesser trochanter. A number of different plates can be used, depending on the type of procedure. The most typical is the one made popular by Maurice Muller and the AO Foundation, namely the blade plate.[11] It comes in various angles and lengths, can be used for all types of osteotomy and requires extremely careful preoperative planning.

The fixation device pierces the lateral aspect of the trochanter and lies on the outside of the diaphysis, requiring periosteal stripping. Patients are typically required to avoid bearing weight for three months, and full recovery is often achieved after six months. With a varus-producing osteotomy, patients are often very concerned about and find it

hard to come to terms with the difference in length and residual limp. There are ways to avoid any alteration in length, but which result in significant changes to the shape of the femoral intramedullary cavity, something the surgeon will wish to avoid in case a hip replacement becomes necessary in the future. Once the bone has consolidated, the plate must be removed which requires a second invasive procedure for the vastus lateralis muscle and fascia lata.



*Figure 1: Minimally-invasive Hueter approach. The procedure generally requires only a 5–6 cm incision. The portal can of course be widened for easier access.*

## Why change

The need to avoid bearing weight and the lengthy recovery period are what make surgeons reluctant to offer a traditional osteotomy to their patients.

However, we believed that there was a way of simplifying the technique and making an osteotomy once more a relevant option by using an approach that is currently on track to regaining its former glory. Having gained confidence from our experience of in situ femoral neck resection during hip replacement surgery, we hypothesized that a femoral correction osteotomy could be performed using a minimally-invasive Hueter approach.

Towards the end of the 1990s, we therefore began offering this technique<sup>[12]</sup> for the treatment of femoroacetabular impingement, and the potential visibility of the anterior proximal metaphysis and femoral epiphysis propelled us to perform the osteotomy via an anterior portal.

Another considerable benefit was that even a complex hip deformity would require only anterior access, thus better preserving the structures for any future joint replacement or revision surgery.

By accessing the femoral neck and proximal femur from the front, the osteotomy can be performed without touching any of the gluteal muscles and without the need to eliminate blood flow to the diaphysis through periosteal stripping. It is also entirely possible, thanks to the access to the femoral epiphysis and joint space, to correct any associated impingement, which is not possible using the traditional technique.

Finally, yet in our view most crucially, the osteotomy line can be a little higher than with the traditional technique, thus having less effect on the shape of the femur. As and when the need for arthroplasty arises, the surgeon will not have to wrestle with any residual femoral deformation caused by the osteotomy.<sup>[13]</sup>

Below, we report on our experience with femoral osteotomy using this anterior approach.

## Femoral osteotomy using the minimally-invasive Hueter anterior approach

This type of surgery is of course primarily indicated for young adults with a severe architectural deformity. Only very exceptionally is it for patients aged over 40 and, as with all types of hip salvage surgery, the cartilage should be carefully assessed (join scan) to ensure no excessive damage. If the Tönnis Grade is higher than 1, the surgeon should reconsider the suitability of this procedure, given the risk of a limited outcome.

We believe that a full assessment is necessary, including dynamic radiographs in abduction and adduction. This is now routinely accompanied by a scan with 3D reconstruction and a calculation of the femoral anteversion.

The more complex cases also benefit from EOS imaging.

The patient is placed on an orthopaedic traction table. The surgical fields are placed in exactly the same manner as for an anterior hip replacement on an extension table. The only difference is that the lateral femur must remain accessible, because the osteotomy correction is performed percutaneously using 2–3 cannulated screws.

In theory, the procedure does not require an image intensifier, although I do recommend using fluoroscopy to check the various stages, so the intensifier should be placed between the patient's legs.

The technique uses a minimally-invasive anterior approach, identical to that used for an arthroplasty between tensor fasciae latae and rectus femoris. The innominate fascia is retracted to expose the anterior circumflex vessels which can be ligated without hesitation. Blood is supplied to the head of femur through the medial circumflex and not this anterior branch.

The capsule is opened using either an inverted V or T incision. The best method is to use traction thread with the capsule flap for easier manipulation and exposure. The capsule opening extends to the anterior tubercle of the greater trochanter, which marks the junction between the neck and metaphysis.

Usually, slightly further back on the proximal aspect of the neck of femur, one can visualise the periosteal structure that supplies blood to the femoral head. This must of course remain intact and the surgeon must take care to avoid the osteotomy line getting too close at any point.

A few millimetres of vastus lateralis may be disinserted at this point to assist the exposure.

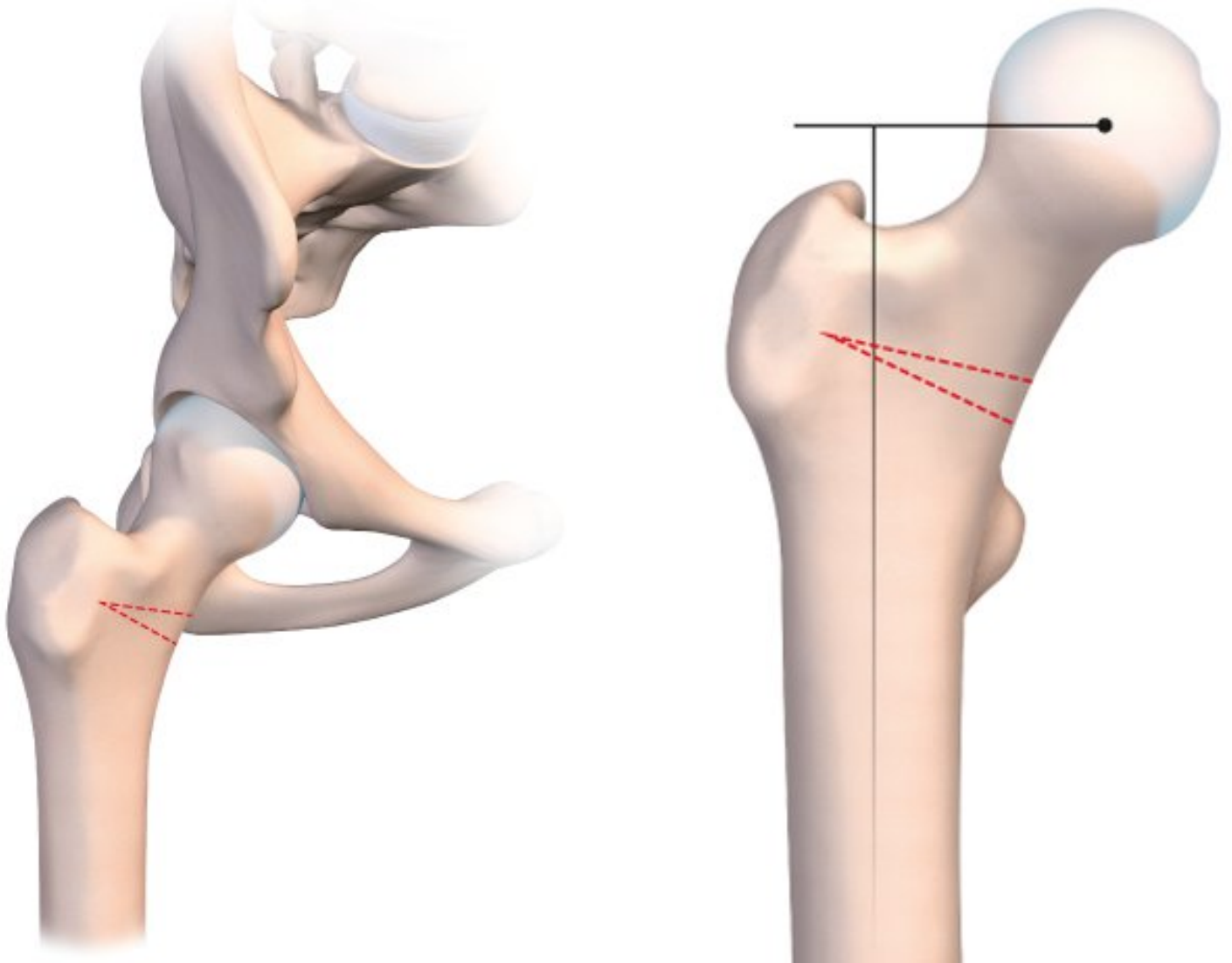
The upper capsule opening extends to the labrum. An arthroscope may now be inserted into the joint, either using the existing portal or by making another entry point slightly offset in order to arrive more centrally into the joint. In this case, the arthroscopy is performed using air and does not require irrigation. The joint can now be placed in traction in order to explore the central compartment of the hip joint cavity. A cartilage assessment is a crucial stage of all salvage surgery. If there is any damage to the labrum or cartilage, the surgeon can of course proceed with reparative surgery. Those with sufficient experience in hip arthroscopy can even turn on the water, remove the retractors and treat the impingement in the usual manner.

It is even possible to dislocate the hip anteriorly if the femoral head requires a particularly specialist procedure such as a mosaicplasty cartilage transplantation.<sup>[14]</sup>

Let us now consider the actual osteotomy.

The height and orientation of the line are determined by the correction required. If the primary deformity is located in the femoral neck (epiphysiolysis), it can be corrected in situ at the very point of the problem. However, we will not cover this particular surgical technique in this article.

The osteotomy line is usually situated at the base of the neck. It should be as horizontal as possible to improve postoperative stability and avoid any slipping or instability (Fig. 2a).



Figures 2a: Femoral varus osteotomy. Presurgical planning and position of the osteotomy wedge to be removed.

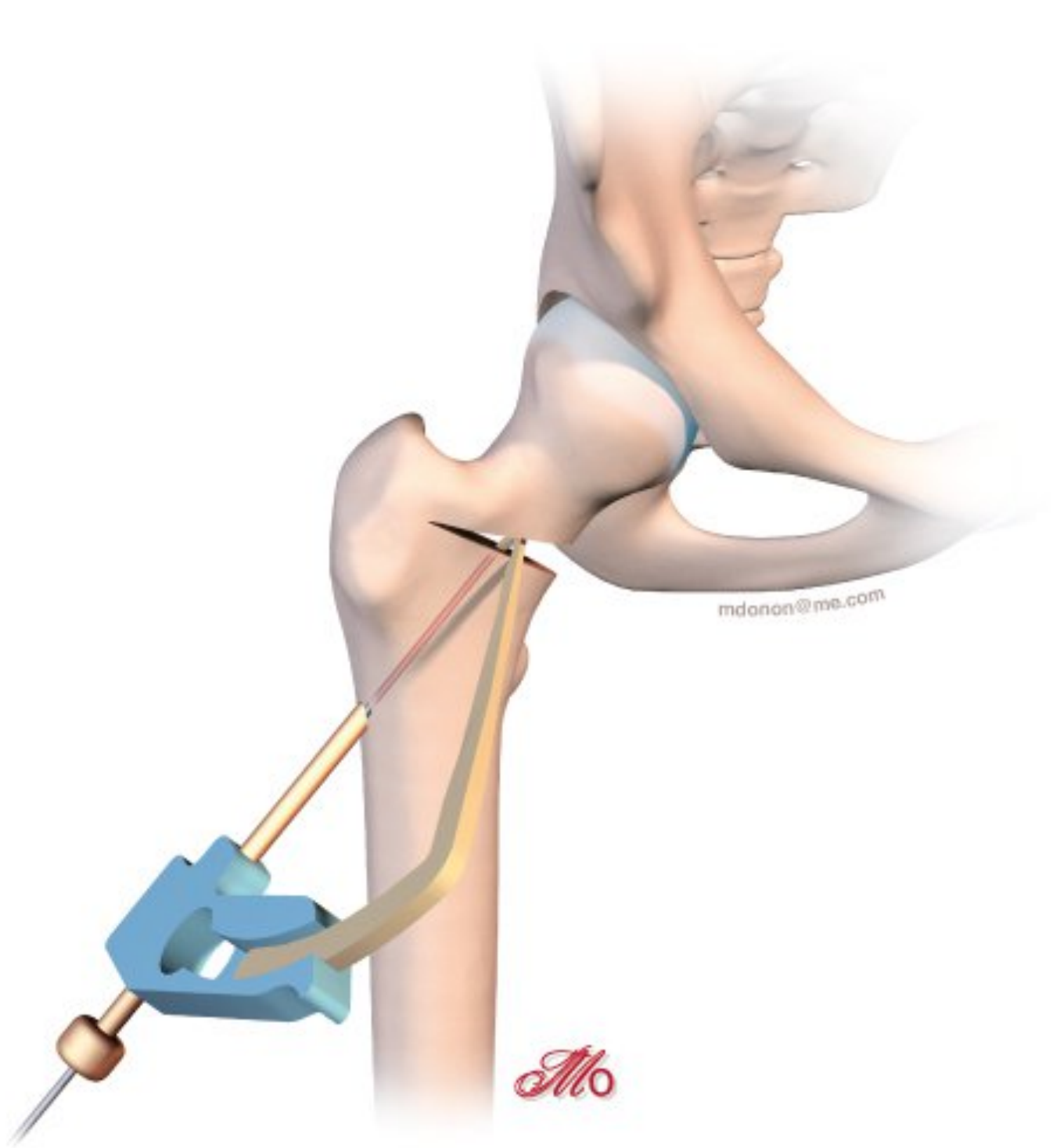
For a varus-producing osteotomy, a wedge can be removed from the medial base, matching the desired angle of correction. The higher the line, the more accurate the wedge calculations must be because it is all too easy to exaggerate the valgus correction by having the line too close to the neck. The preoperative planning must be just as meticulous as for the traditional technique. We use new computer tools to simplify and even simulate this type of surgery.

In principle, I suggest having the first line as horizontally as possible, then placing the second line above the first to create the osteotomy wedge. The wedge should be incomplete and should not entirely section the lateral femur by the greater trochanter. The cancellous bone in this region will naturally break more towards the top in general. Simply stop the oscillating saw halfway between the lateral and medial cortex, just at the point of insertion of vastus lateralis beneath the trochanteric tubercle. The orthopaedic table is then put in pulse mode, and the open osteotomy line will close fairly naturally. If there is any resistance, the line can be completed laterally using a chisel in order to encourage the fracture towards the greater trochanter.

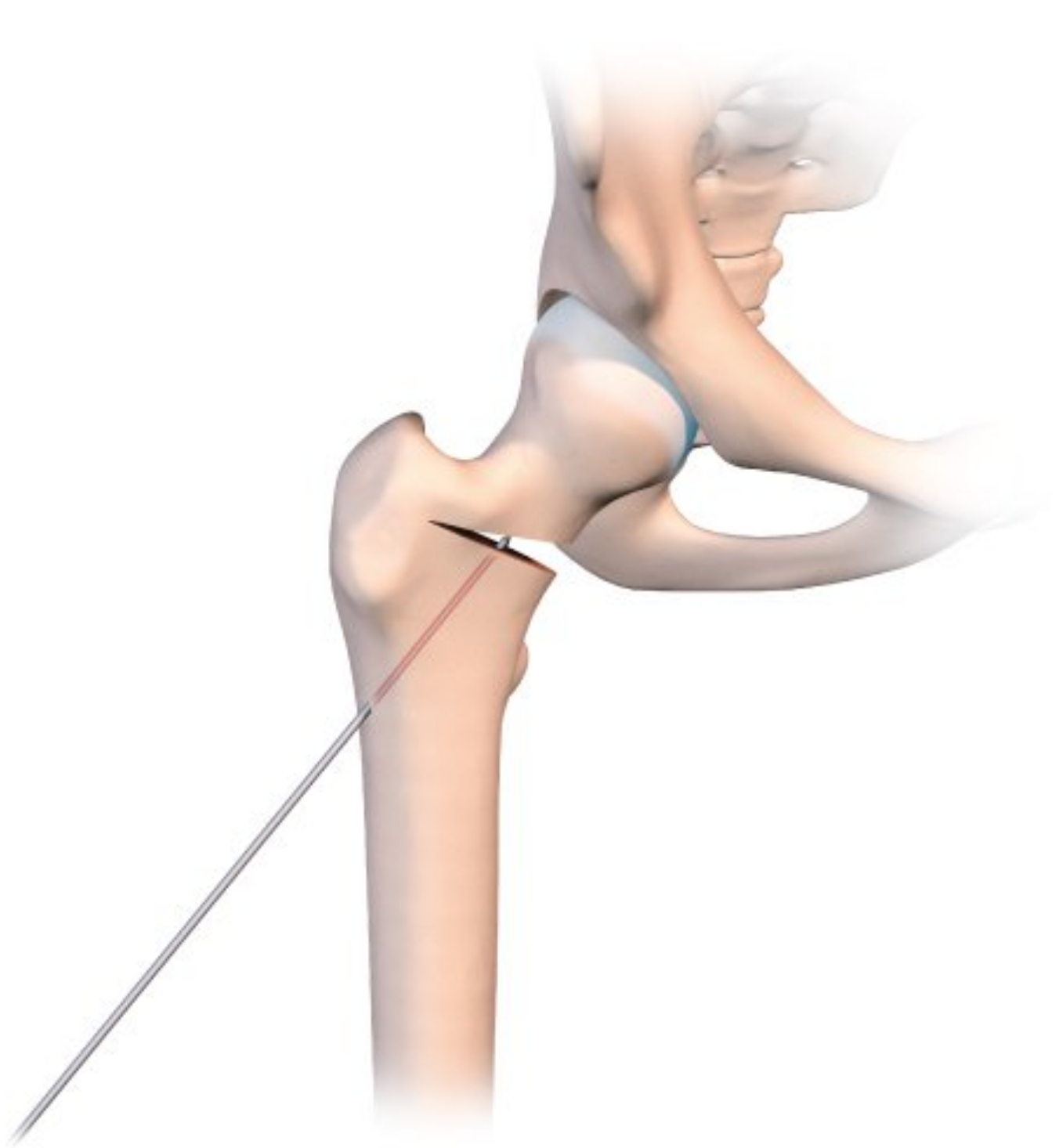
At no point should the gluteal muscles or fascia lata be involved, and by remaining intact these muscular/aponeurotic structures will act as a lateral tension band.

This osteotomy is easy to repair, using the same technique as for a normal badly impacted fracture of the base of the neck of femur, with two or three large diameter cannulated screws.

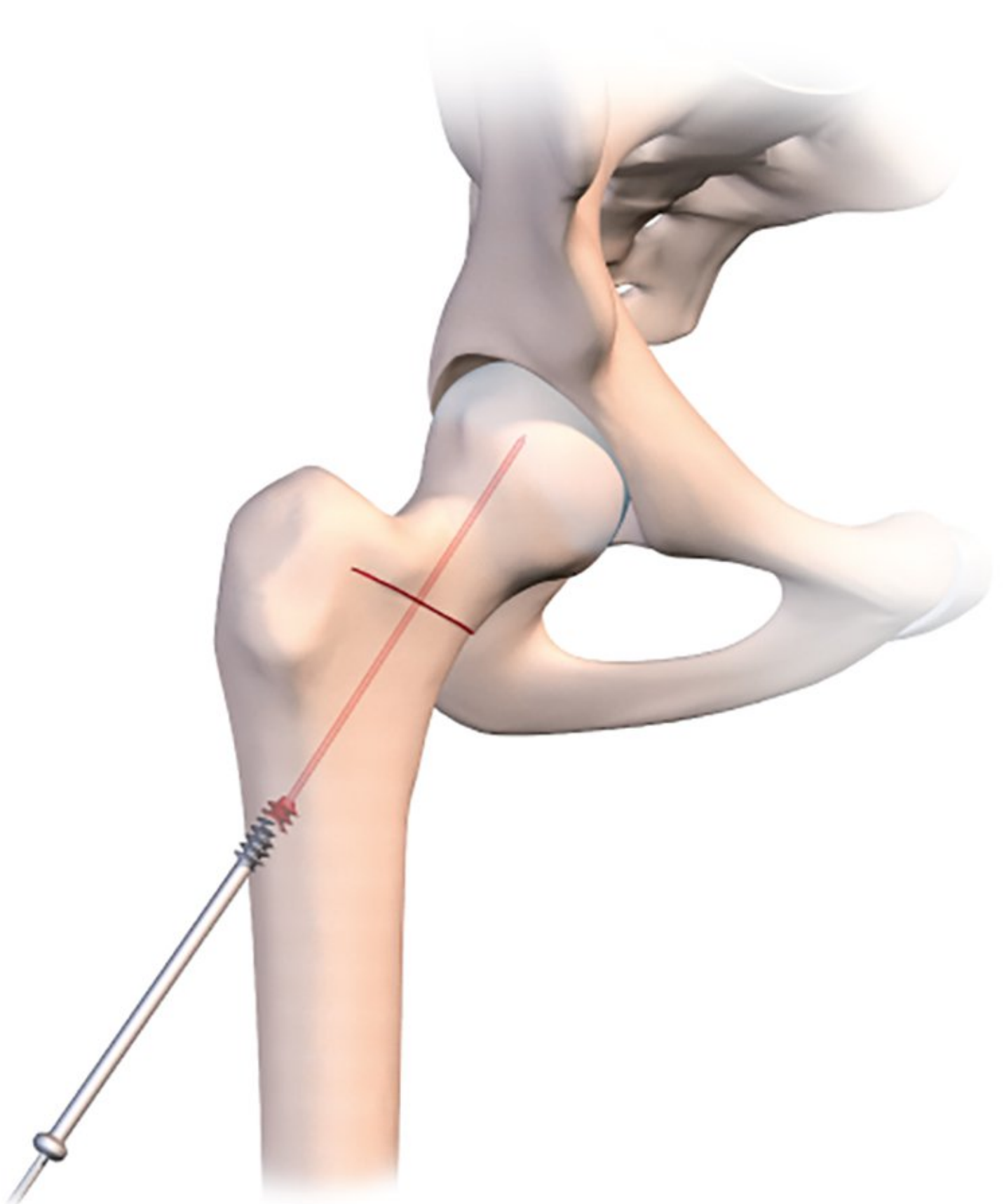
Just before using the orthopaedic table to begin the compression, it is a good idea to use a tibial drill guide (as for cruciate ligament repair) (Figs. 2b, c, d).



*Figures 2b: Inserting a pin with the tibial drill guide used for ACL repair.*

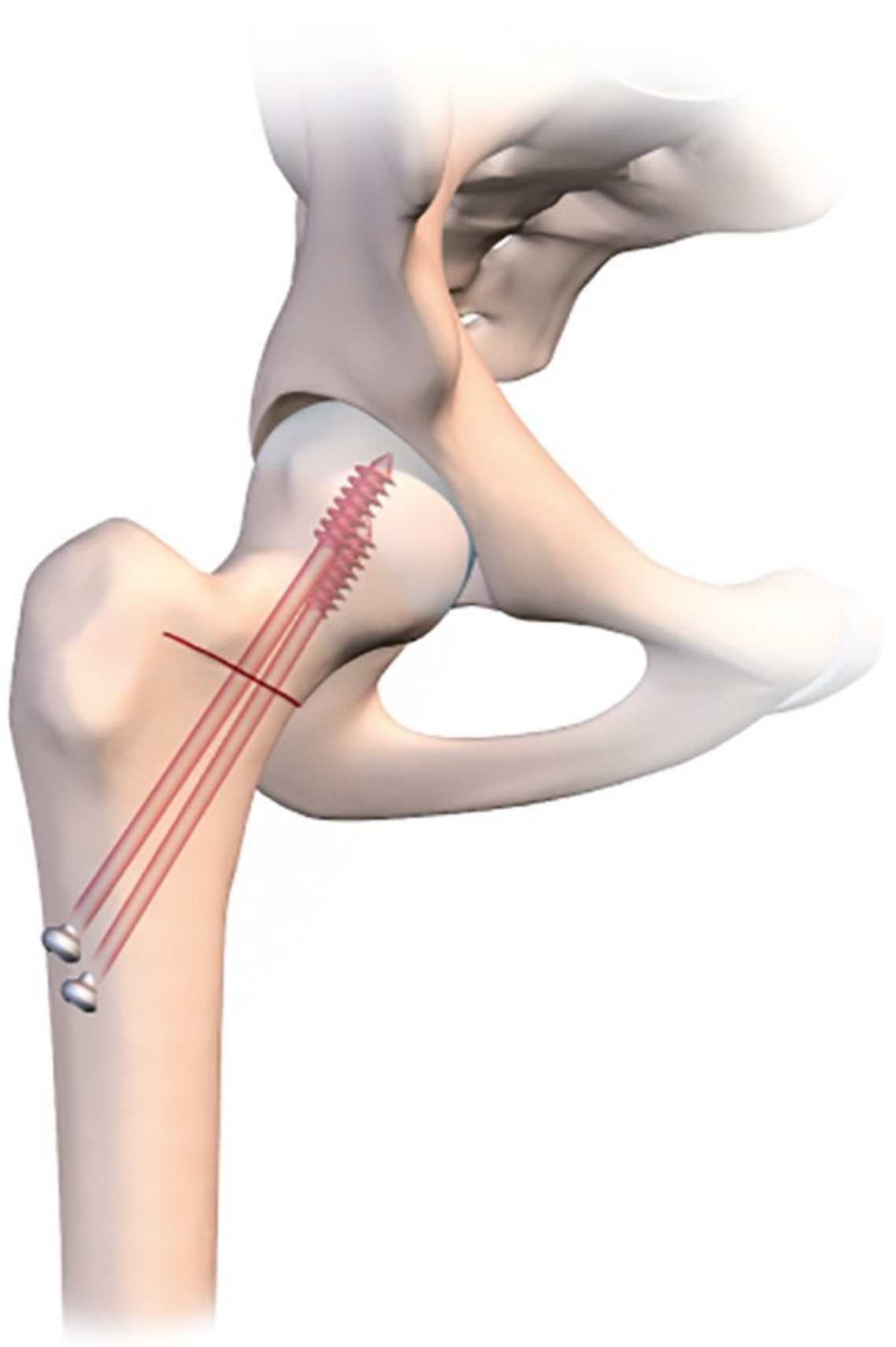


*Figures 2c: The pin sits within the osteotomy line and goes no further.*



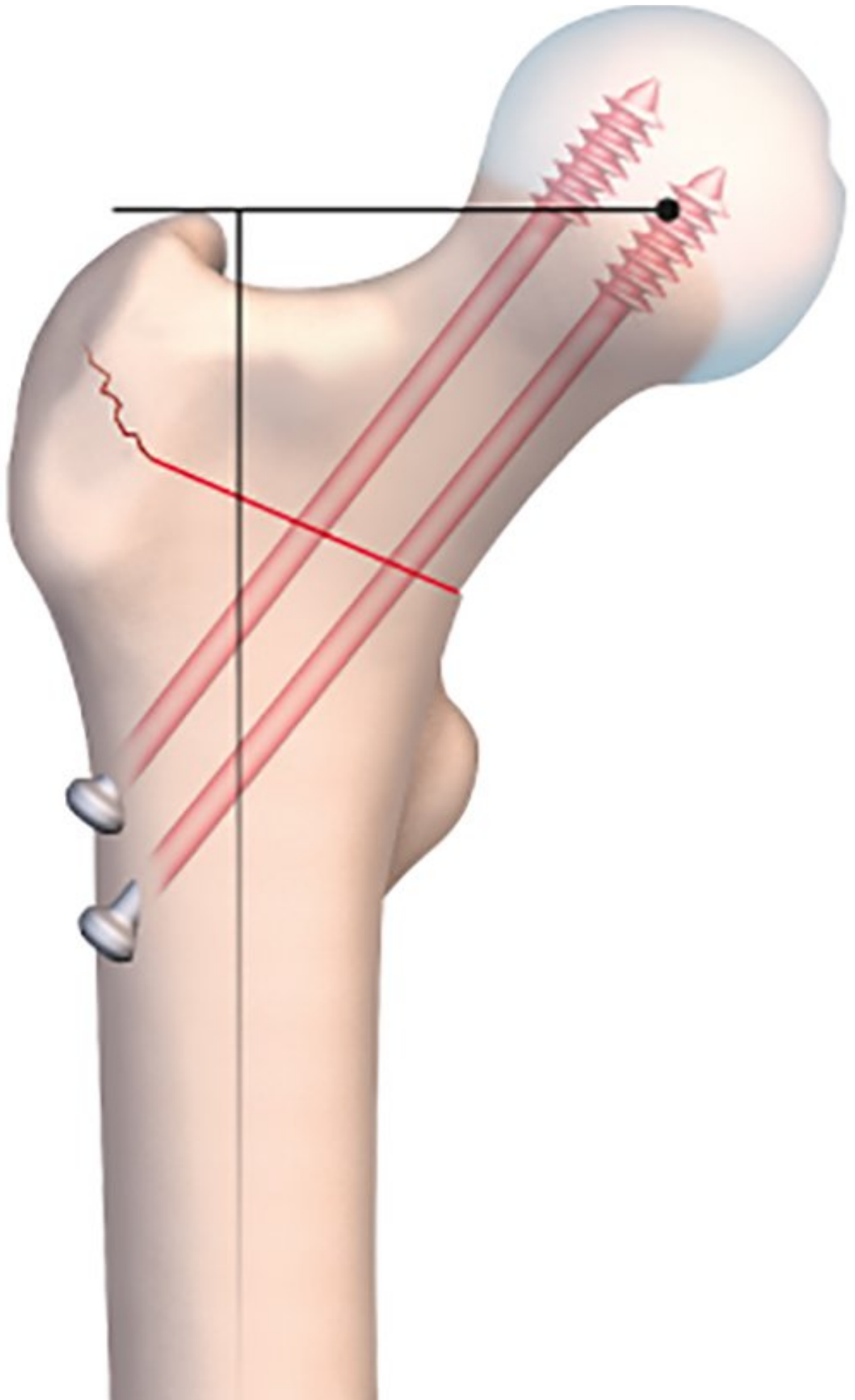
*Figures 2d: The osteotomy line is placed under compression using the osteotomy table; the closure of the line results in osteoclasis in the greater trochanter. The pin is then pushed into the head to stabilise the fixation, and a cannulated screw is used to guarantee osteosynthesis.*

This makes it much easier to guide a pin into the osteotomy line that has just been created. The pin should of course sit just within the osteotomy line, without going any further. Applying compression will close the line and fix the pin in the neck and head of femur. With the osteotomy line closed and the pin in place, the final stage is to insert a 7mm cannulated screw to stabilize the fixation. A second or even third screw may be used if necessary. The image intensifier should be used to check the correct placement of the screws (Fig. 2e).



*Figures 2e-f: The fixation is completed with a second screw. Final assembly with correction.*

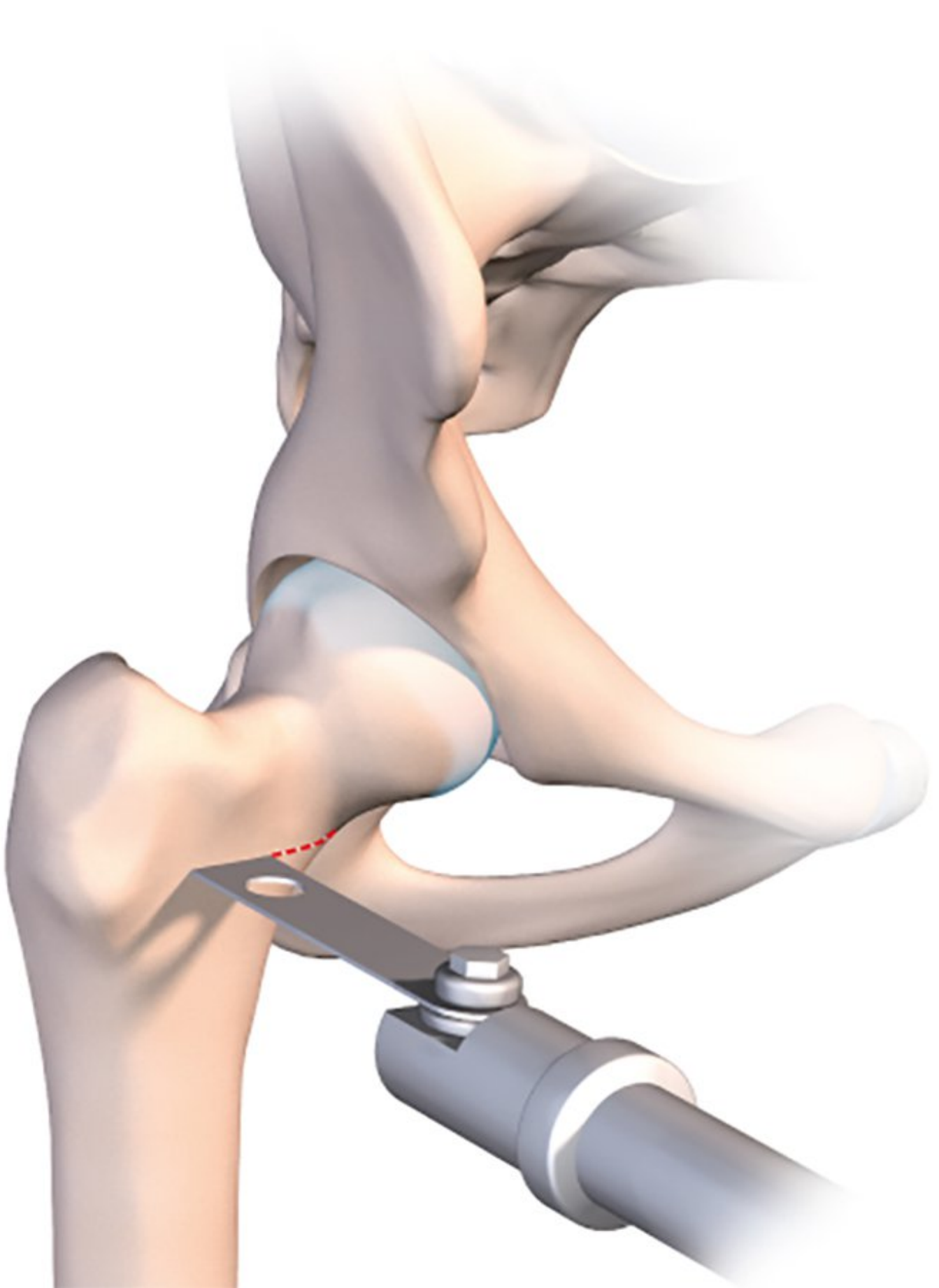





*Figures 2e-f: The fixation is completed with a second screw. Final assembly with correction.*

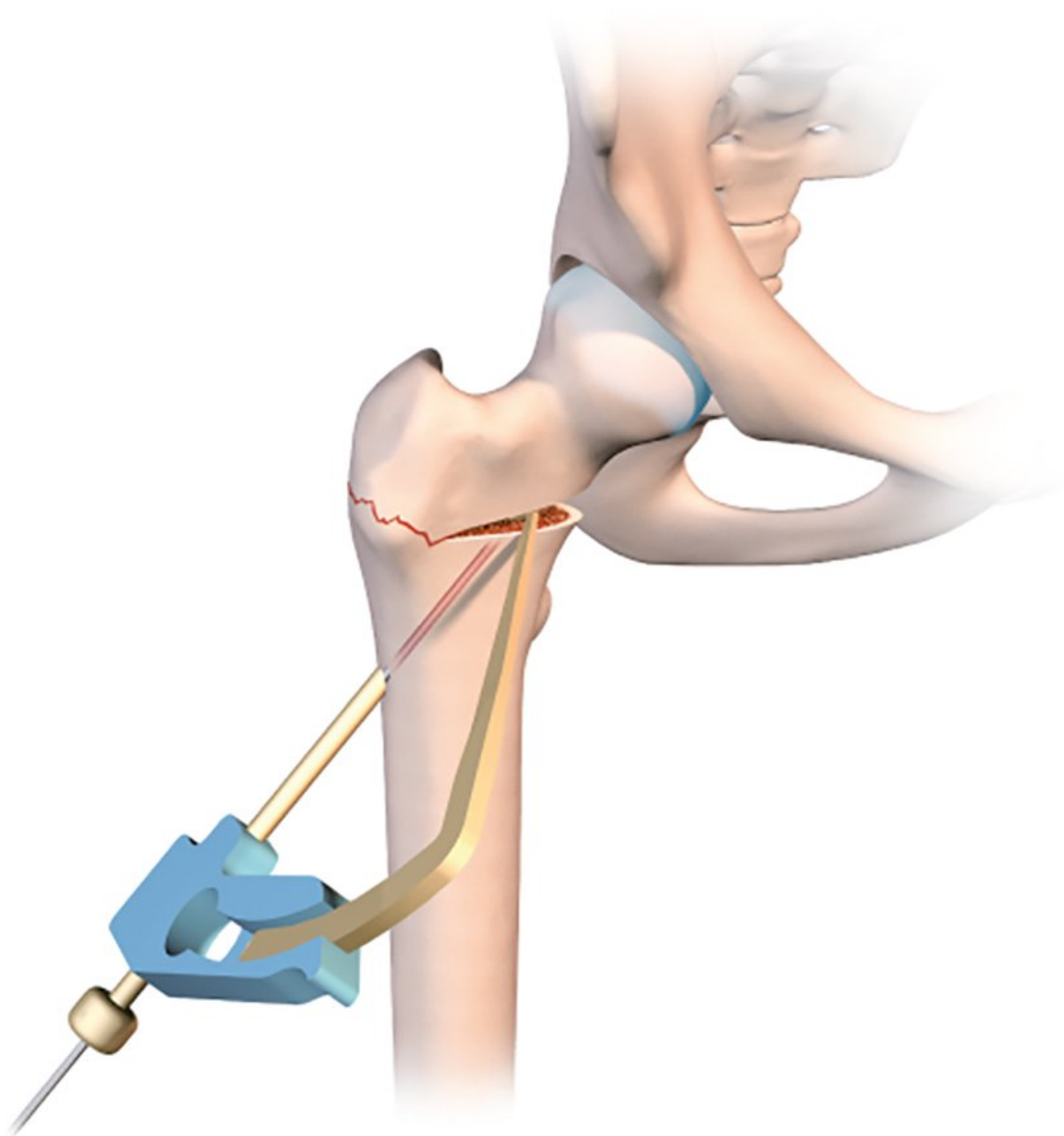
For a valgus-producing osteotomy, the technique is even simpler. One single osteotomy line is required in the medial half of the femur (Fig. 3a).



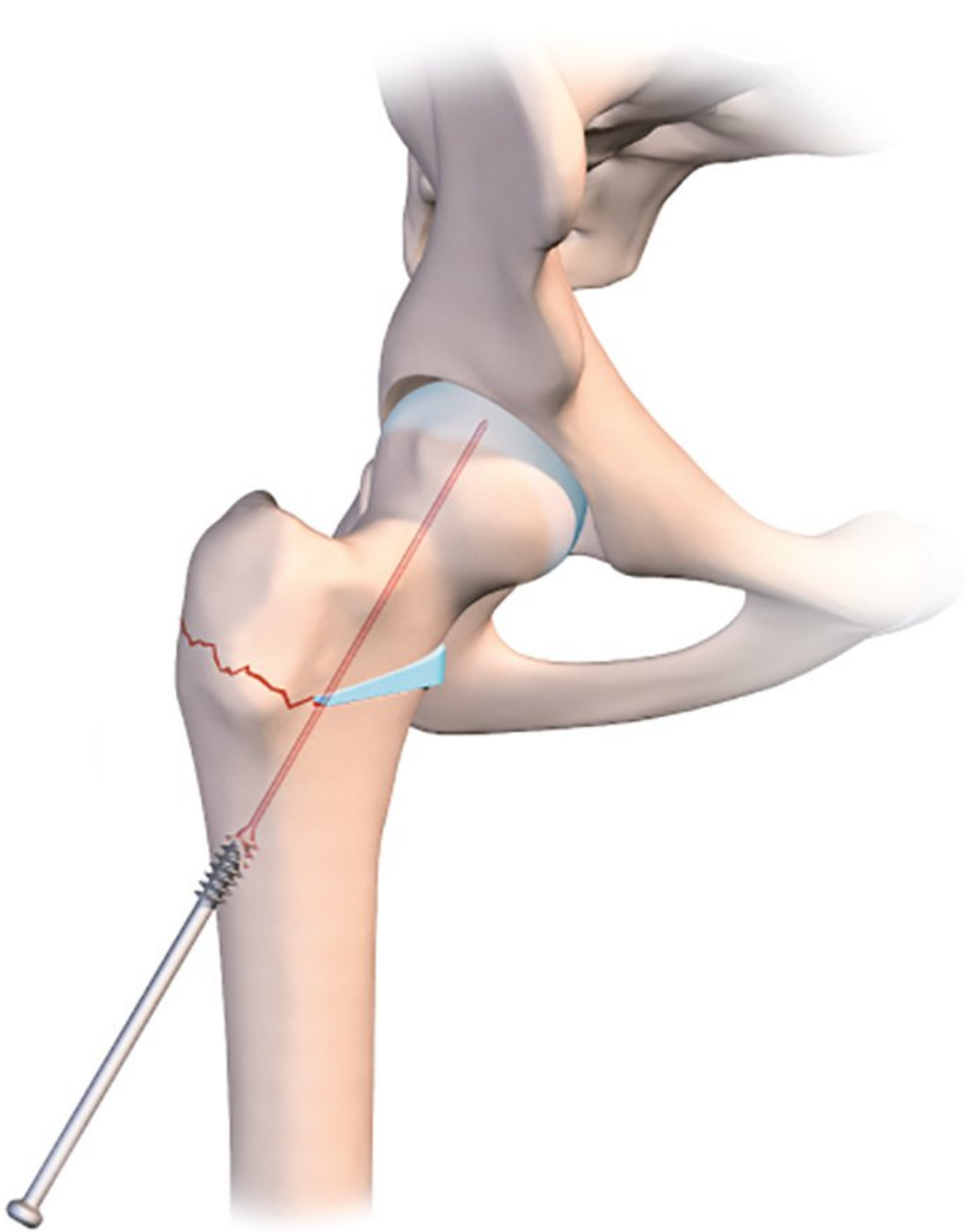
*Figures 3a: Incomplete osteotomy line perpendicular to the diaphysis. It terminates beneath the trochanteric tubercle to avoid damage to the gluteus minimus tendon. The limb is then placed in traction using the orthopaedic table. The osteotomy line is opened to the angle needed to correct the deformation. The angle is checked using an image intensifier.*

Simply applying traction along the line of the femur will naturally cause the osteotomy line to open. The line should be incomplete, and the lateral part should again be created as for a guided bone fracture. The medial section of the line is then opened by putting the orthopaedic table in traction.

However, the fixation process is trickier, because the cannulated screw must not create any new compression which would close the line (Figs. 3b, c, d). I recommend using a large diameter fully-threaded cortical screw as close as possible to the medial cortex into the femoral neck where the bone stock quality is highest. A second more lateral screw will maintain a good degree of compression on the lateral part of the line. In addition, here the screw will embed into the cancellous bone of the greater trochanter.



*Figures 3b: An arthroscopic tibial drill guide, as used for ACL repair, is placed in the open line. A pin is inserted to hold a cannulated screw. The gap is held open using a hydroxyapatite wedge, which is harder than the bone fragments used for tibial osteotomy. Reinforced PEEK wedges are perfect for this type of surgery. A first screw is placed in the head.*



*Figure 3c: A strong and solid HAP wedge keep the valgus osteotomy open and the wire is pushed inside the femoral head*

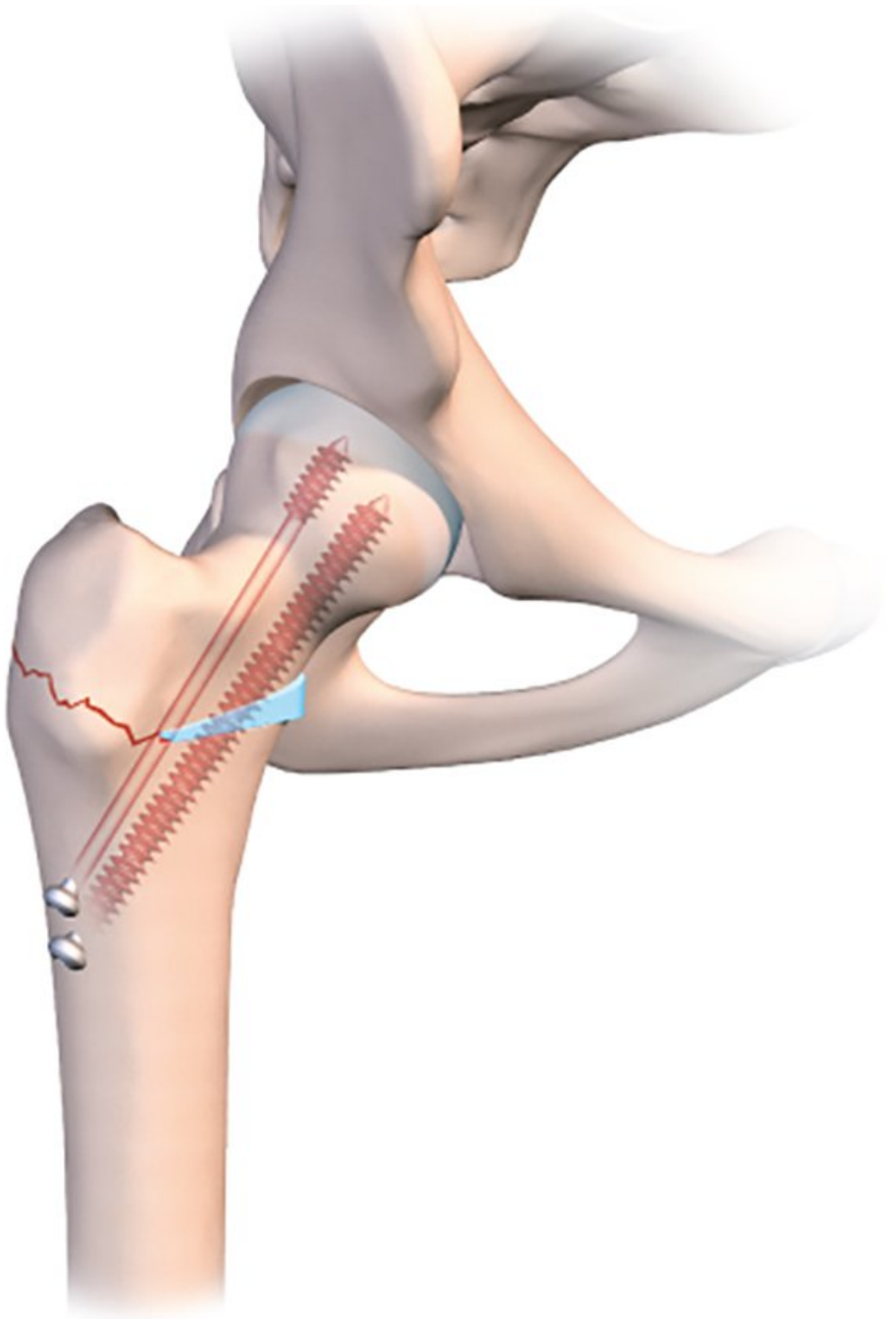


Figure 3d: A second fully-threaded screw stabilises the fixation and prevents any loss of correction.

It is quite possible and even desirable to improve the outcome and avoid any loss of correction upon weight-bearing, to insert a hydroxyapatite wedge into the open line (Fig. 3e).

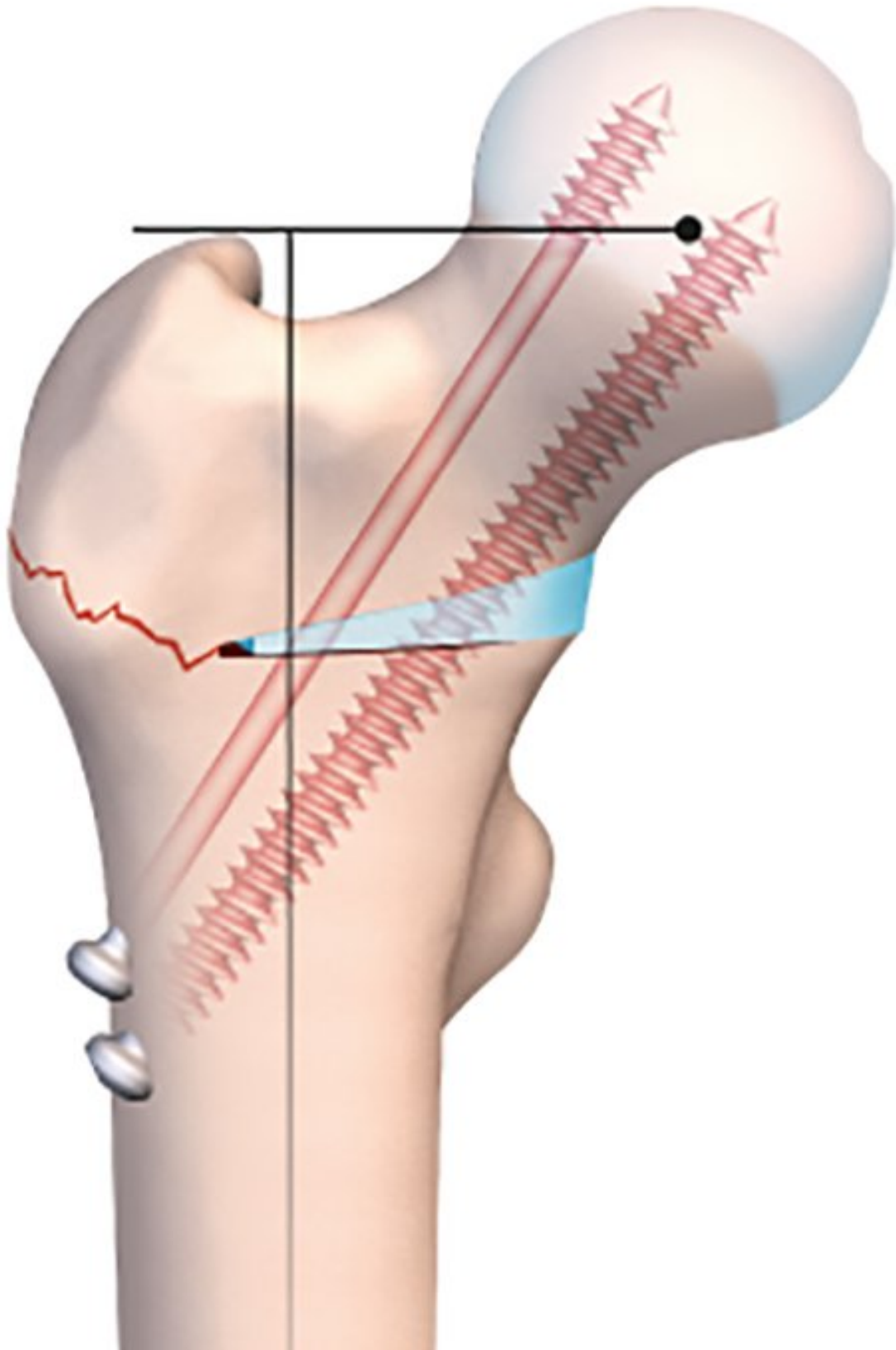




Figure 3e: Final fixation.

A wedge could be harvested from the iliac crest in order to fill the gap, but this would be insufficient on its own to produce the desired degree of valgus. When the patient tries to bear weight on the region, the line will be unable to close and crush the wedge. The medial-most fully-threaded screw will be more effective if seated in the lateral cortex of the lateral diaphysis and firmly embedded in the head.

This technique is also very useful for version correction osteotomies at the base of the neck to treat excessive anteversion of the femoral neck. The problem can be corrected at the point of the problem instead of at the femoral diaphysis as when using an intramedullary nail. The need for rotation requires complete mobilisation of the neck, involving a double osteotomy line in order to avoid mobilising the greater trochanter. The first horizontal line terminates at the lower insertion of the greater trochanter on the trochanteric tubercle (Figs 4b and c), with the second line running perpendicular and vertically terminating in the greater trochanter (Fig. 4d) just behind the origin of the femoral neck, leaving the periosteum intact. The line is usually incomplete.



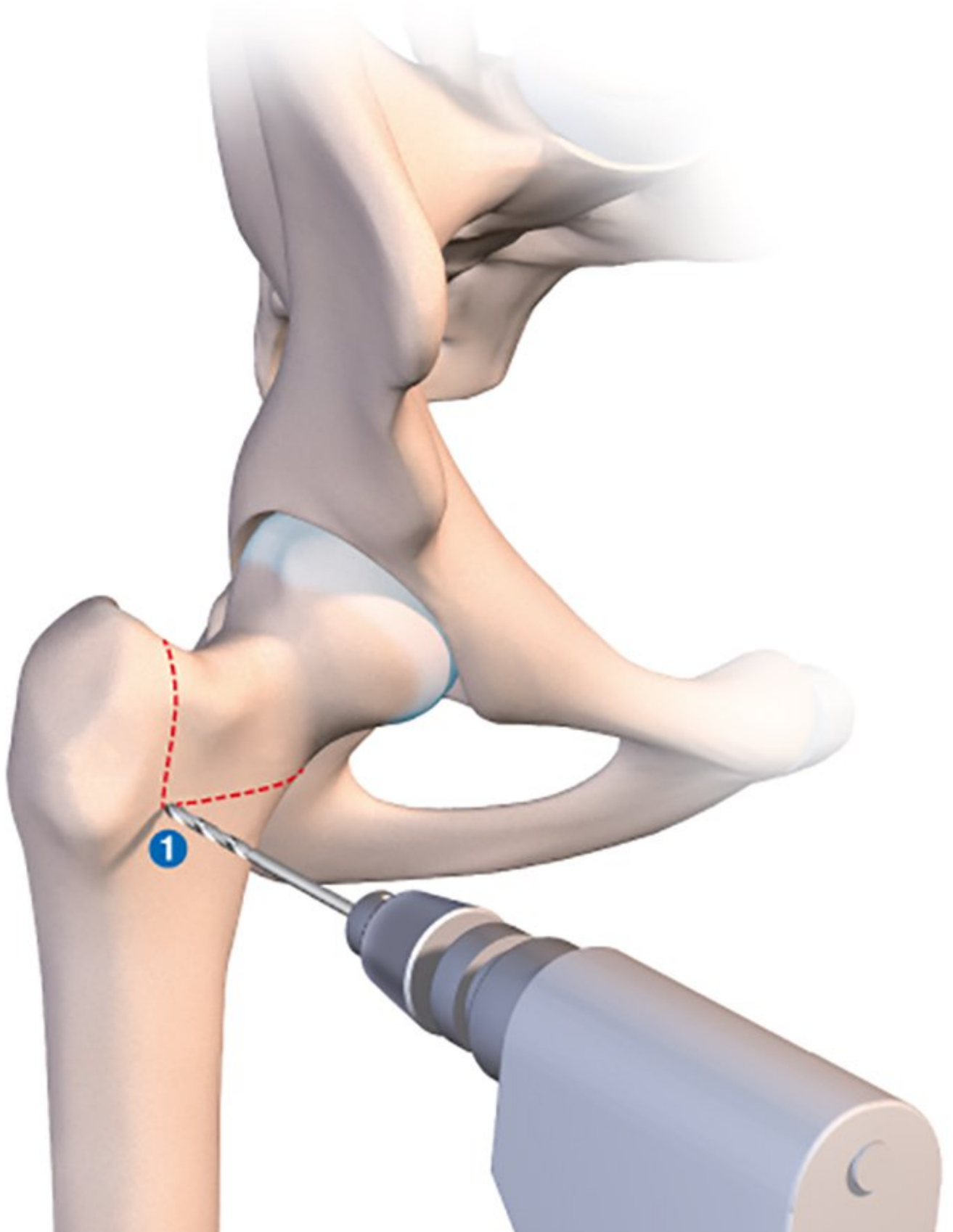


Figure 4b: Using fluoroscopy to locate the junction between the two osteotomy lines.

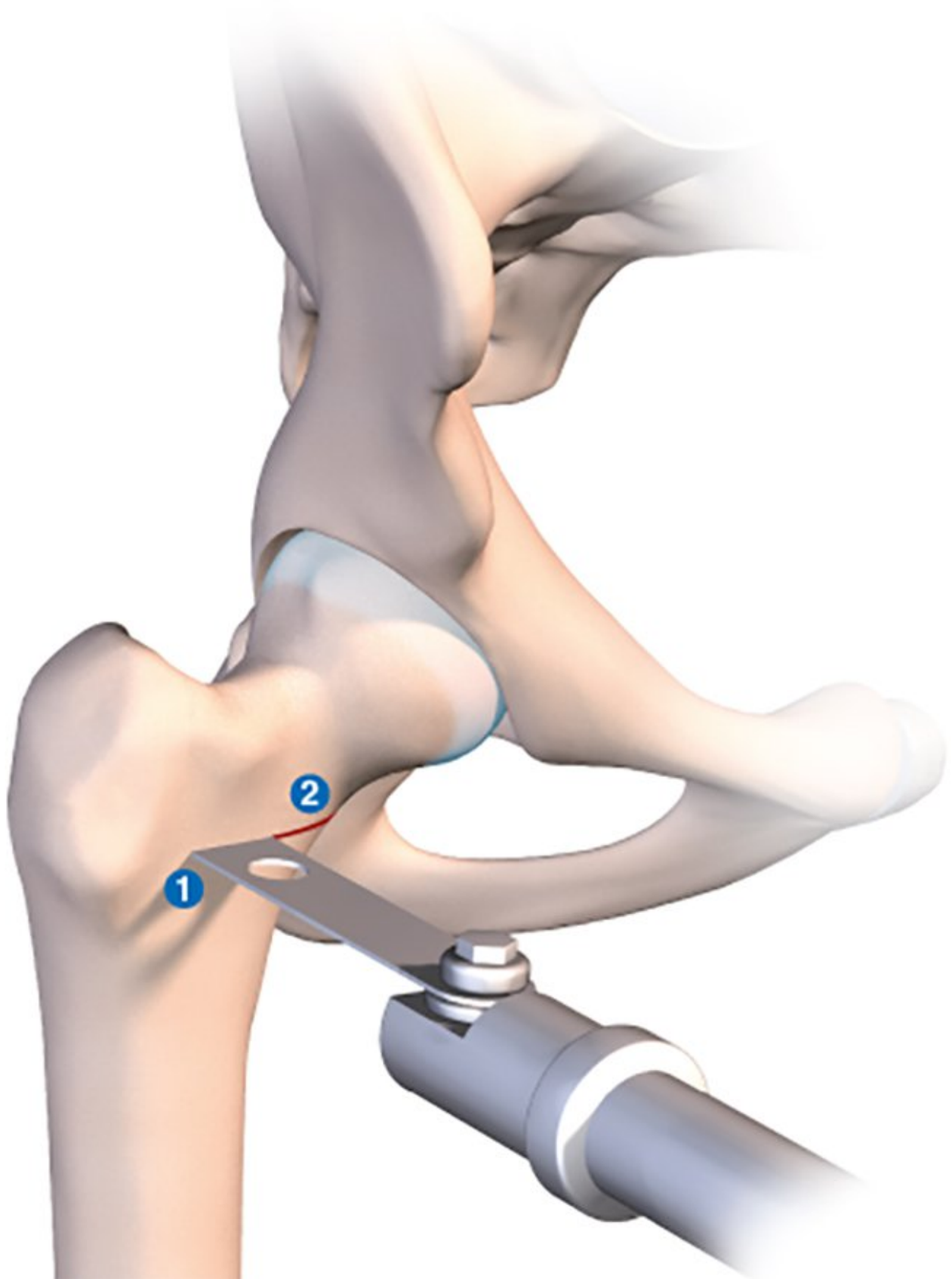


Figure 4c: Horizontal line.

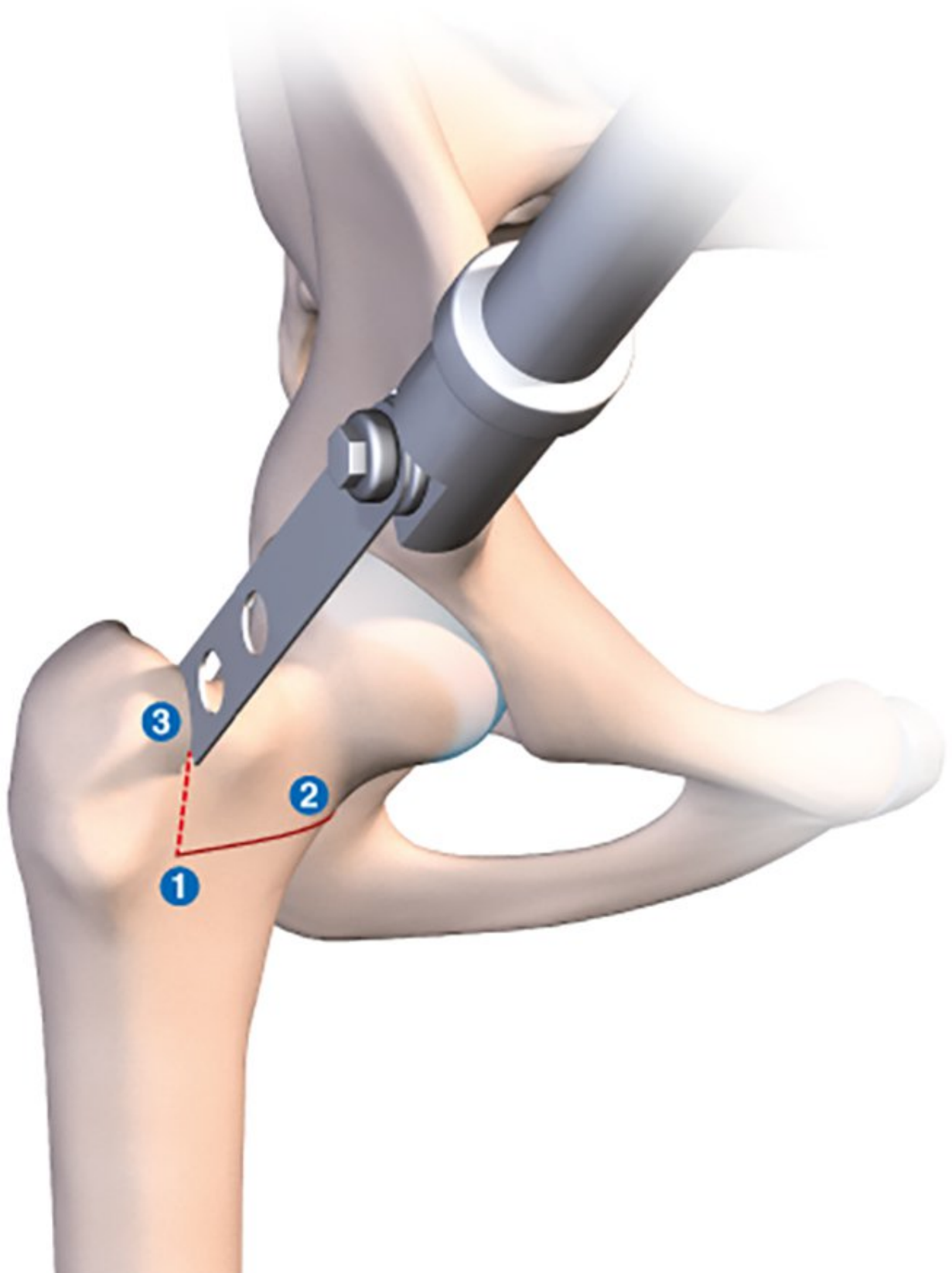
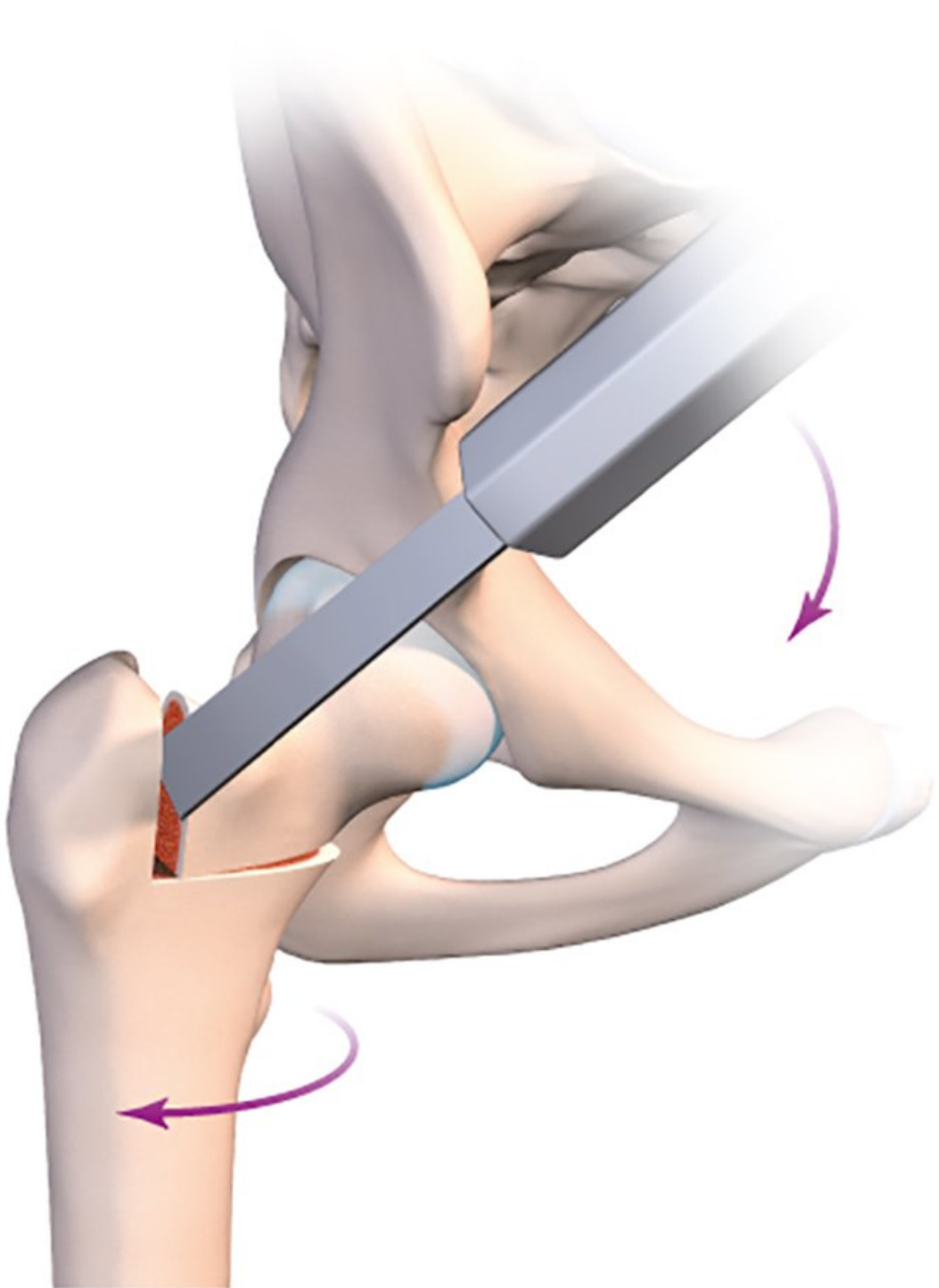


Figure 4d: The osteotomy line penetrates approximately 1cm into the anterior cortex. It must not touch the posterior cortex due to the proximity of the median circumflex vessels.

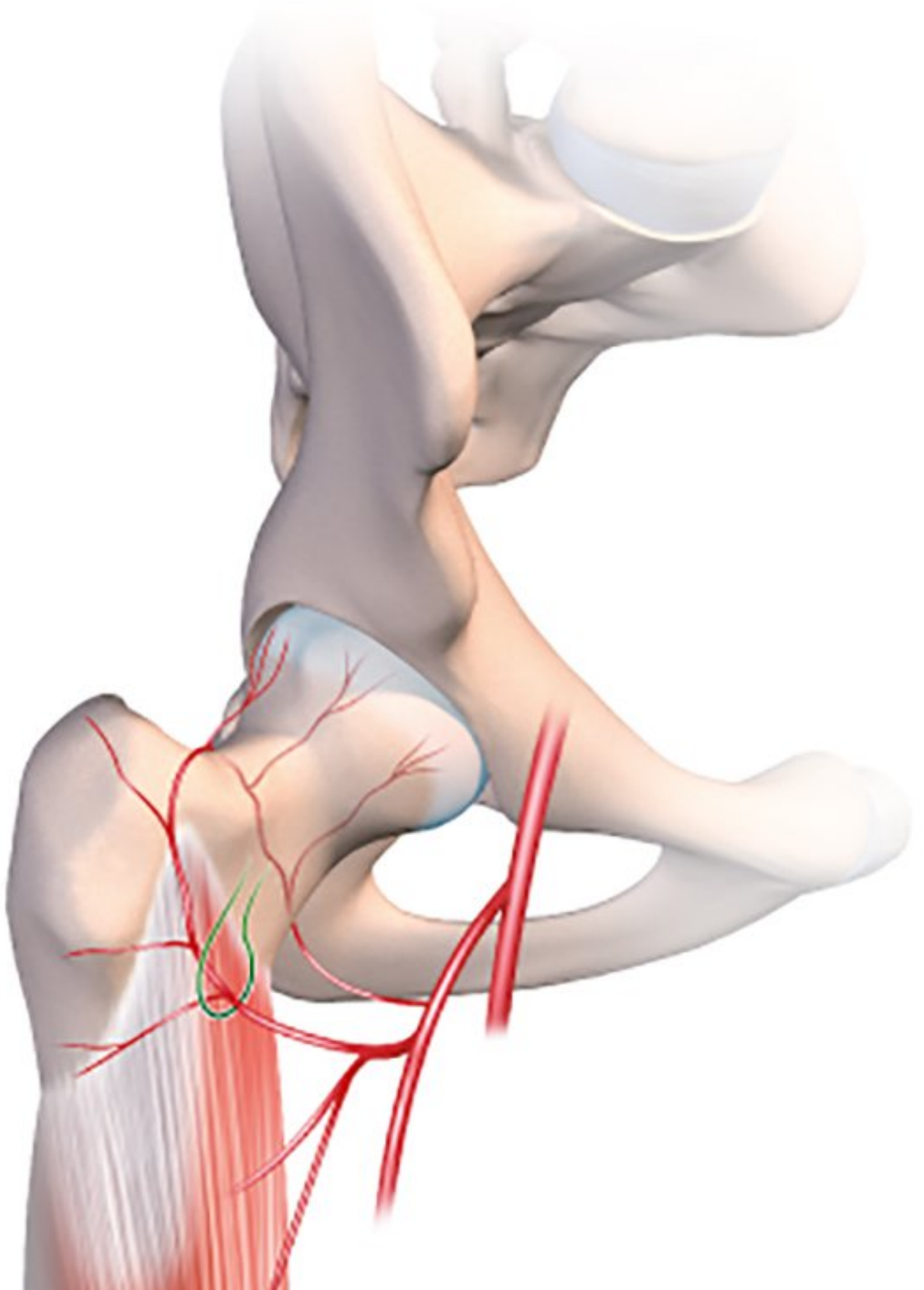
In order to guarantee avoiding the blood vessels when creating this second vertical line, I recommend resection of the anterior cortex only. This will leave a posterior bony hinge to protect the median circumflex vessels.

The foot is placed in sharp medial rotation, then an osteotome is inserted into the vertical line. The foot and knee are then returned to neutral rotation (Fig. 4e). The osteotome holds the neck in medial rotation by opening the derotation osteotomy. The posterior cortex will break naturally and automatically create a posterior hinge.



*Figure 4e: The limb is placed in medial rotation using the orthopaedic table. A 15/20mm osteotome is used to hold the neck and epiphysis in medial rotation whilst the orthopaedic table is gently adjusted to produce lateral rotation. This leaves a posterior hinge to protect the median circumflex vessels.*

No tool or instrument should bypass this potentially dangerous region. If the vertical line is sufficiently posterior, there is no great risk since the vessels run in close contact to the femoral neck (Fig 4a). It reaches the neck after passing between the medial and lateral obturator muscles.





*Figure 4a: Blood supply to the proximal femur. The blood supply of the femoral neck comes almost entirely from the medial circumflex femoral artery. The anterior circumflex, which is ligated, plays only a minor role in ensuring the blood supply to the anterior femoral neck.*

Before making the two osteotomy lines, the whole procedure can be made easier by drilling a 3.5mm hole in the anterior cortex anterior to where the two perpendicular lines will join, then using an image intensifier to ensure the optimal positioning of the two osteotomy lines (Fig 4b).

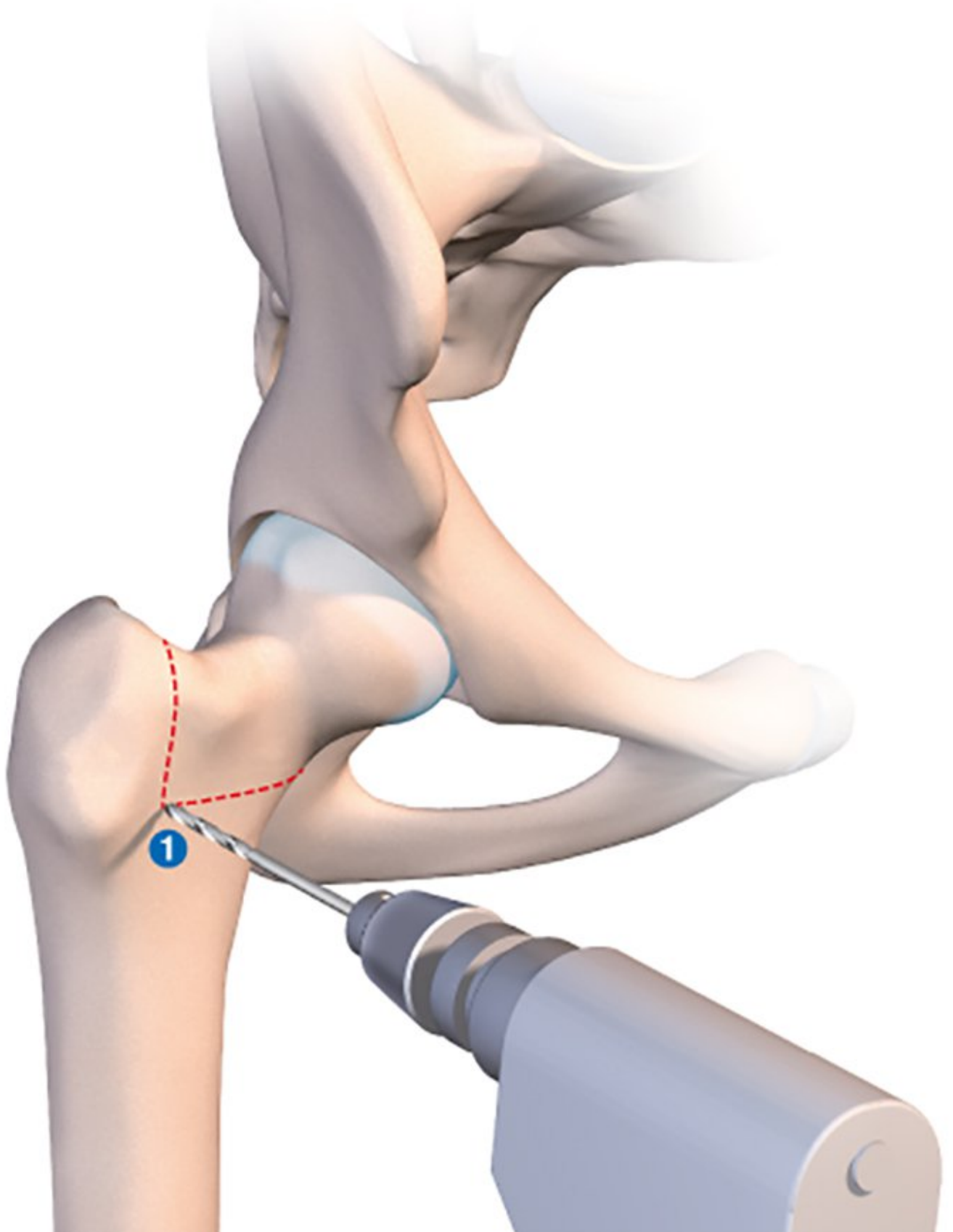
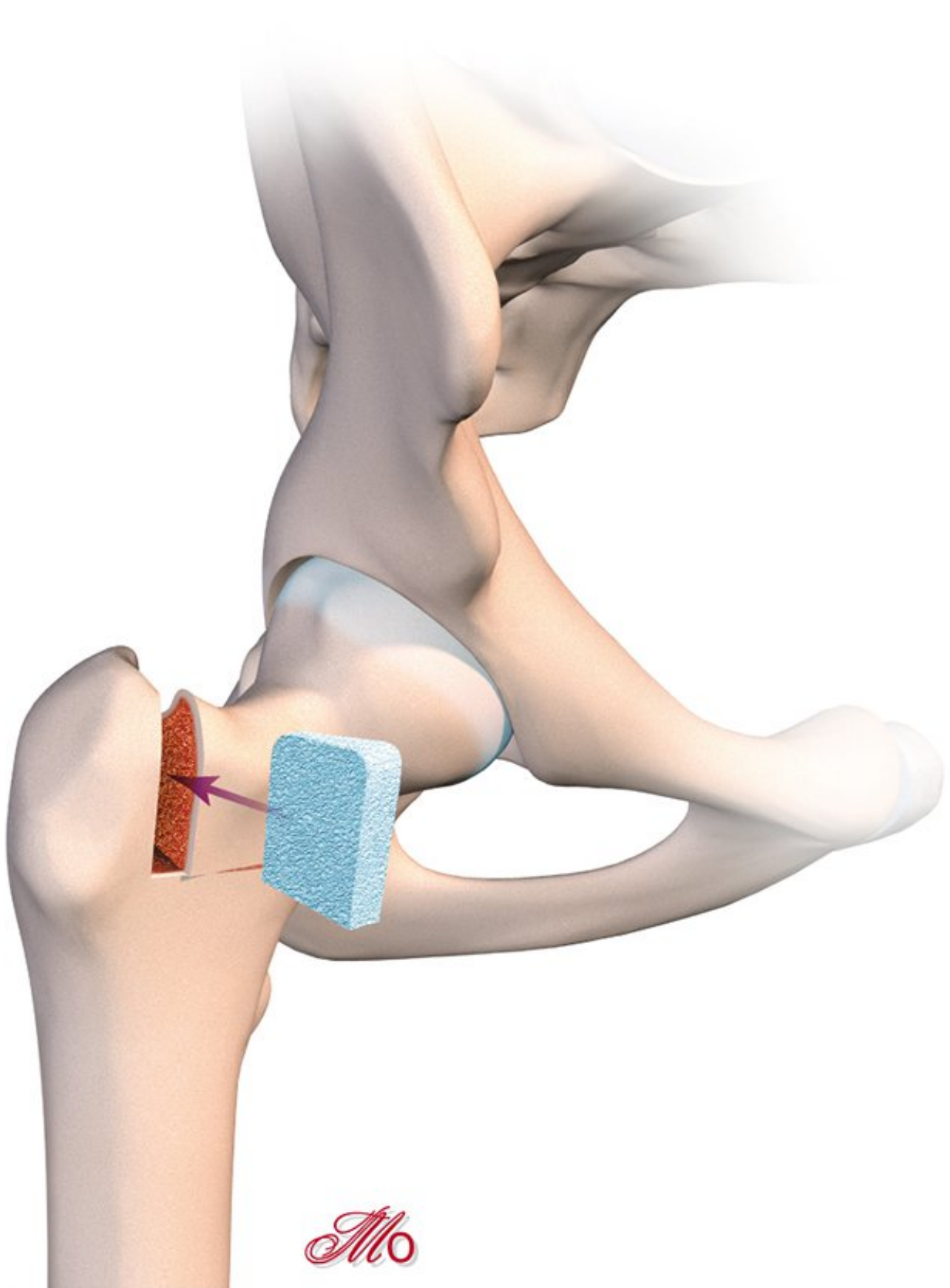


Figure 4b: Using fluoroscopy to locate the junction between the two osteotomy lines.

With derotation osteotomies, we always fill open lines using a small allograft fragment (Figs 4f and g).



*Figure 4f: A lyophilized bone wedge is inserted to produce the desired angle of correction. The bone fragments used for tibial osteotomies usually work very well.*

*Mo*



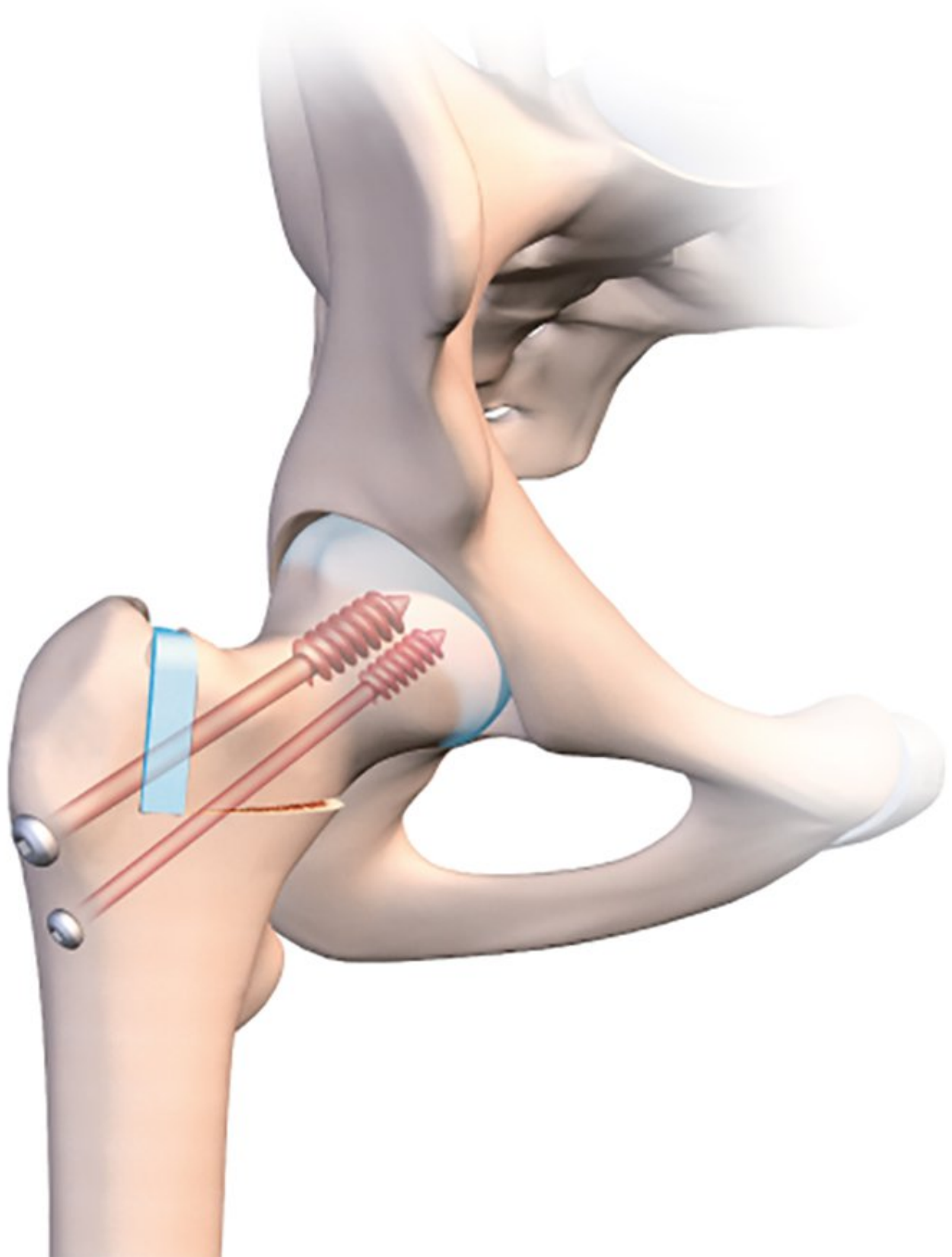


Figure 4g: Fixation using two lateral screws.

## Results

We began performing this procedure in 2008, and in the decade since we have corrected 15 hips in 14 patients. They were all young patients with an average age of 24 (range 17–34) for whom replacement surgery was a very aggressive option. Ten of the patients were women (11 hips) and four were men. Average follow-up is 4 years (range 6 months–10 years).

Nine of the corrections involved a varus-producing osteotomy, five a valgus-producing osteotomy and one femoral derotation for excessive femoral anteversion.

Two patients underwent a simultaneous periacetabular osteotomy. In one of these two cases, involving a young 27-year old patient, the periacetabular and varus osteotomy were accompanied by a cartilage transplantation using the mosaicplasty technique with anterior femoral dislocation. All three procedures were of course performed through the same portal.

If there were any femoroacetabular impingement requiring targeted treatment,[15] the procedure was performed prior to the osteotomy.

We found that recovery was much faster than with the traditional technique, and in 14 out of the 15 cases the patient was able to bear full weight on the joint within two months.

All hips consolidated in under three months, except one which took closer to four months.

In this particular case, involving a relatively high osteotomy line, we had instructed the patient to wait four months before bearing weight.

The Harris Hip Score increased from a preoperative 60 to 90 as of the final follow-up (range 80–97).

Unfortunately, in one of the very first cases we handled involving a valgus-producing osteotomy, we lost some of the correction obtained immediately after the surgery. This was due to an allograft wedge that became impacted and was unable to sustain the correction. Since then we have changed the way we perform valgus corrections. We now fill the gap using a hydroxyapatite wedge, which is firmer, then complete the procedure using a fully-threaded cannulated screw.

One patient had already undergone several procedures prior to her osteotomy and was given a total hip replacement after three years. However, even after the replacement surgery her Harris score was fairly low.

Not one patient across the whole series presented any femoral head necrosis.

## Discussion

Femoral osteotomies for correcting varus or valgus deformities and version abnormalities are usually performed using a lateral approach and a plate;[16] derotation osteotomy can also use a superior portal and an intramedullary nail.[17]

In both cases, the primary and notable disadvantage is the residual effect on the surrounding muscle tissue. The use of a plate requires avulsion of the vastus lateralis, whereas a nail gets inserted via the gluteal muscles and is accompanied by a loss of intramedullary blood supply due to the reaming.

Since developing this technique a dozen years ago, we no longer see any need to use the old lateral method. This approach is attractive for many reasons, because it is intermuscular, interneural and never implicates the gluteals which are essential for rapid recovery of a fluid gait.

Patient comfort is the primary motivation for this change. It did not take us long to notice the speed of recovery and the fact that patients found it much easier to return weight to the limb.

We were somewhat surprised to see that several patients had almost stopped needing their crutches by the 6-week check-up.

After the traditional lateral surgery, it takes roughly three months before patients can again bear weight on the leg, and we have always felt that the recovery time is much longer.[16, 18]

As with anterior portal hip replacements, the fact that the gluteal muscles remain intact promotes faster weight-bearing. Our patients now only need to spend one night in hospital, although it could probably also be performed as an outpatient procedure.

However, despite not being particularly difficult it does require precise technical execution. The osteotomy line must terminate in the greater trochanter for both valgus- and varus-producing osteotomies. If the lateral line, which is a controlled fracture, terminates too high in the femoral neck, there is a probable risk of femoral neck instability. We have encountered this problem just once. Recovery was also slower, and we were unable to authorise weight-bearing until four months post-surgery. Nevertheless, there was no fixation instability and the final outcome was satisfactory.

With derotation osteotomies of the femoral neck, the most common technique probably currently involves the use of an intramedullary nail and resection of the diaphysis beneath the greater trochanter using an intramedullary saw.[17, 19] This is a reliable and well-documented technique, but one that requires sufficient experience of locked nails and the use of an intramedullary saw. This highly specific instrument is unfortunately not available everywhere, and so our solution may be more appropriate.

Another benefit of this technique is that it treats the problem in the exact location of the deformity and does not alter the diaphysis. The intramedullary technique may possibly be better for patients with concomitant problems of the knee, the patella in particular, with our technique being more effective in cases of specific hip-related problems. Finally, both valgus and version correction can be performed simultaneously, something that is obviously quite unthinkable using the intramedullary solution. Removing the intramedullary nail is also a little more complicated than simply removing two screws.

Hip dysplasia is often a multi-factorial condition. In some cases, as in our series or that of Buly,[19] the femoral osteotomy must be accompanied by an additional surgical procedure such as periacetabular osteotomy, hip arthroscopy or mosaicplasty. In both of the techniques described above, this additional procedure will require additional incisions or portals.

Our technique however has the advantage of involving one single small incision through which any additional procedure can also be performed with ease. With a periacetabular osteotomy,[20] the scar extends to the iliac crest with or without avulsion of the anterior superior iliac spine.

We are unable to comment much on blood loss because this issue was not covered by our study; however, once again it is likely that the reduction in soft tissue release equates to less blood loss.

One further benefit of this technique is that the changes to the proximal femur cause fewer problems for patients. The osteotomy line is a little higher than for the traditional technique and has less effect on the overall shape of the femoral metaphysis. The more streamlined fixation material also means that, in theory, there should be no difficulties inserting a femoral implant.[8, 13] Finally, but not least of all, if in the future the patient requires a joint replacement, the surgeon can simply re-use the osteotomy portal, provided of course that he or she is familiar with hip arthroplasty via the anterior approach.

Many surgeons still have doubts over one particular issue, namely the proximity of the circumflex vessels. The ascending lateral circumflex bundle has only a minimal role in supplying blood to the femoral head. For Dewar[21] the head of femur obtains 82% of its blood supply from the medial circumflex artery, and the neck of femur 67%. Ligation of the lateral circumflex vessels is therefore perfectly safe. Nevertheless, it is crucial that the medial circumflex bundle remains intact. These vessels arrive from the posterior neck, running first across the posterior aspect of the lateral obturator tendon.[22, 23] As they pass through the capsule they are perfectly visible and they must of course be identified before the osteotomy begins. For varus and valgus correction, there is no risk of damage in this area and the vessels are in principle protected by the lateral obturator and sit well away from the bone. The vertical osteotomy line that we suggest for a derotation osteotomy is much more critical. It should pass well behind, almost into the greater trochanter. Crossing the posterior cortex will not work, since this is where the rotational hinge sits and it will spontaneously break. The risk of necrosis is a false alarm, based on a misunderstanding of the finer anatomical points of the blood supply to the proximal femur. It should be reassuring to know that we have never had any problems with any of our patients.

## Conclusion

Proximal femoral osteotomy is no longer a common procedure. The lengthy recovery period and the success of hip replacement surgery have considerably undermined its value. Nevertheless, in a young osteoarthritis-free adult it still represents a highly relevant solution.

Moreover, our particular technique is much simpler with a much easier recovery period for our patients. It can even be performed simultaneously to a periacetabular osteotomy, using the same portal.

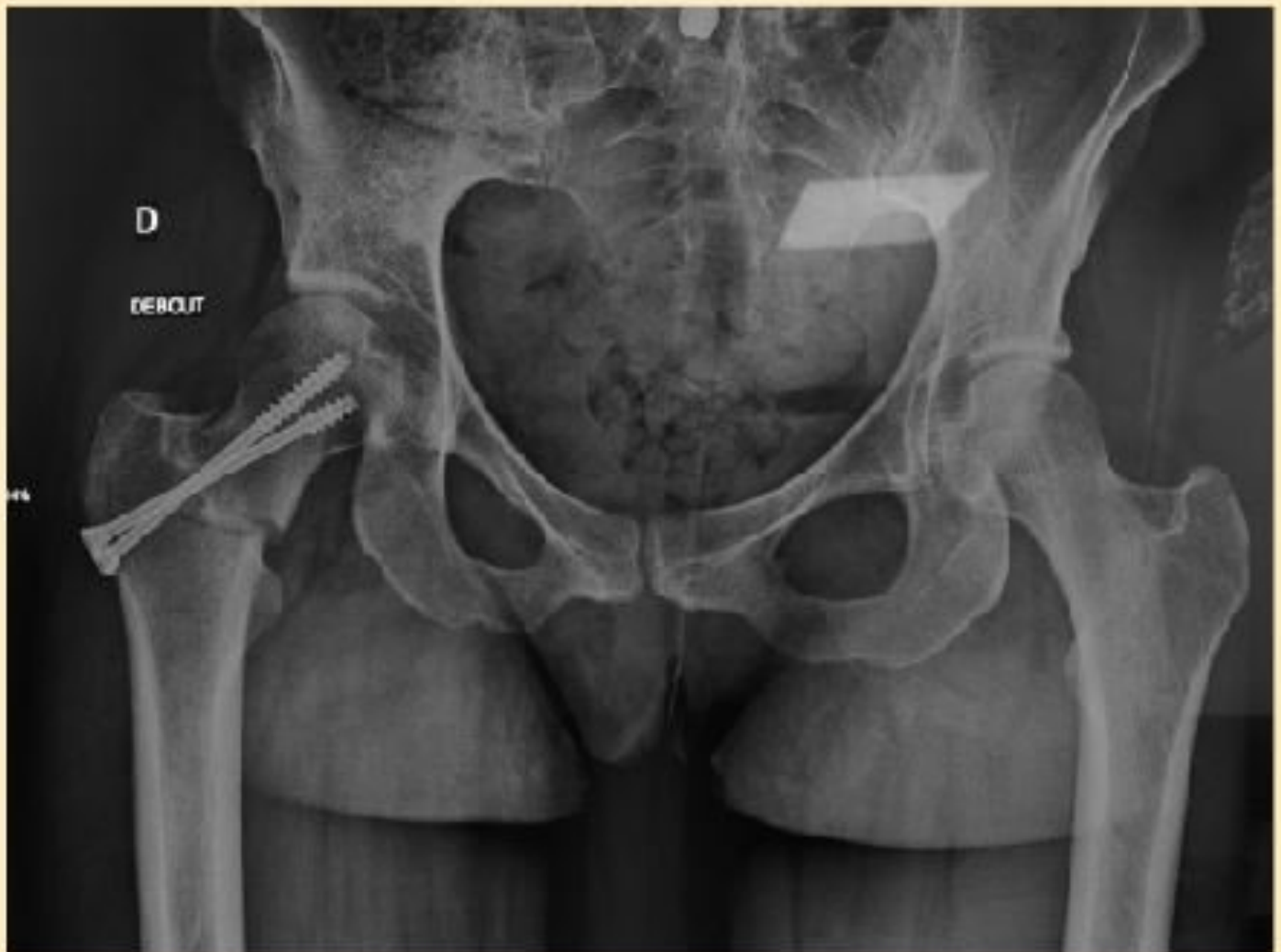The surgery requires a thorough technique, but for anyone who regularly carries out hip replacements via the anterior approach, it poses no particular problems. The femoral head is resected in almost exactly the same way as for replacement surgery.

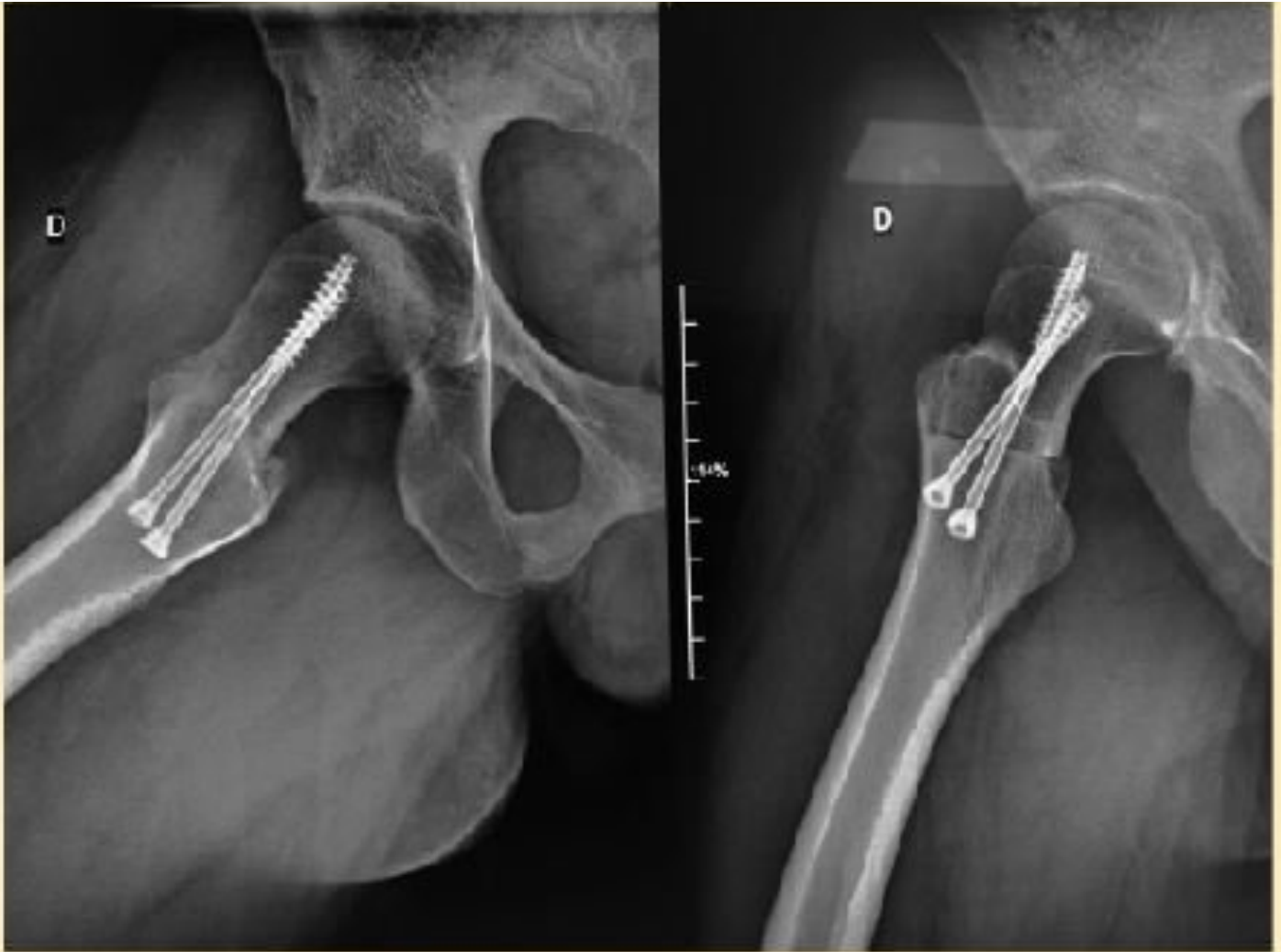Our decade of experience using this technique, the consistent results and the absence of any vascular complications mean we offer it to our patients without second thought.

Any surgeon interested in hip salvage surgery should include proximal femoral osteotomy in his box of tricks.

## Some clinical cases

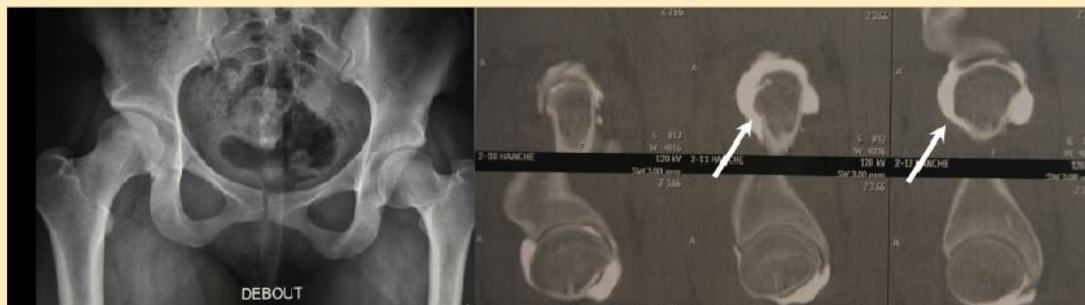### Case 1: Femoral derotation



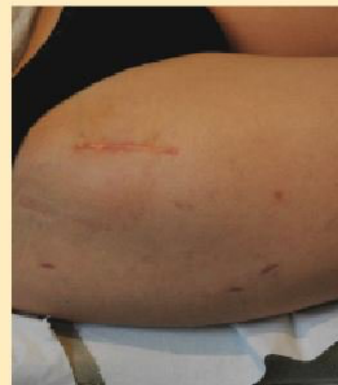

*Postoperative radiographs.*

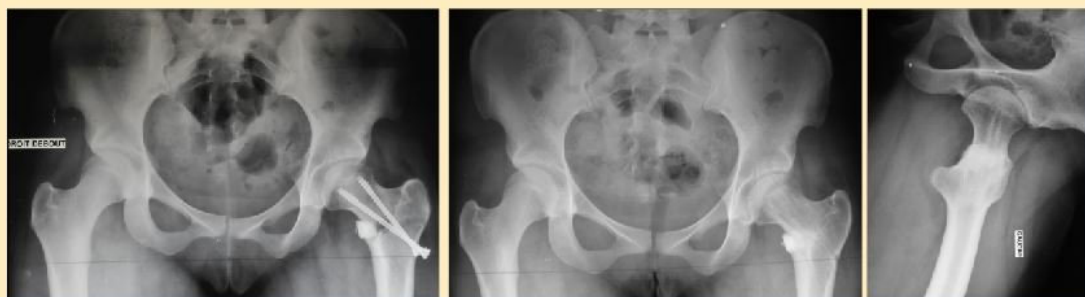**Case 2: Valgus-producing osteotomy - Young woman, 17 years old. Hip pain on Coxa vara. Conflict and bump on the profile**



*Preoperative assessment. The joint scan reveals an anterior bump which is causing the femoroacetabular impingement.*



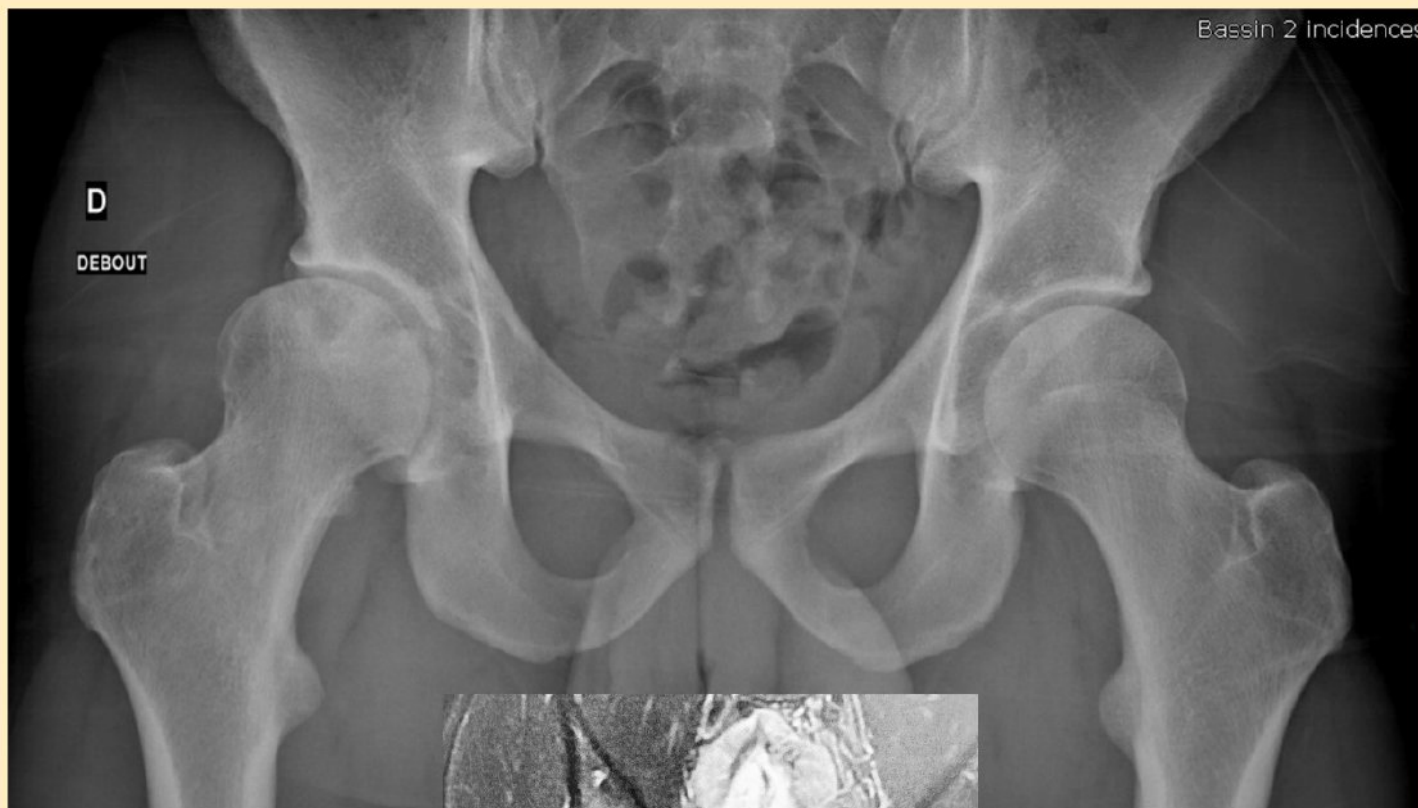*Anterior scar.*

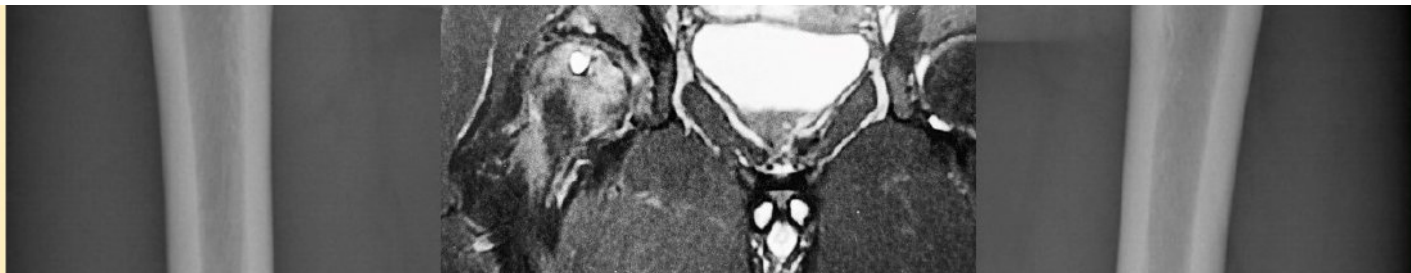


*Valgus correction using a hydroxyapatite wedge and two screws.*

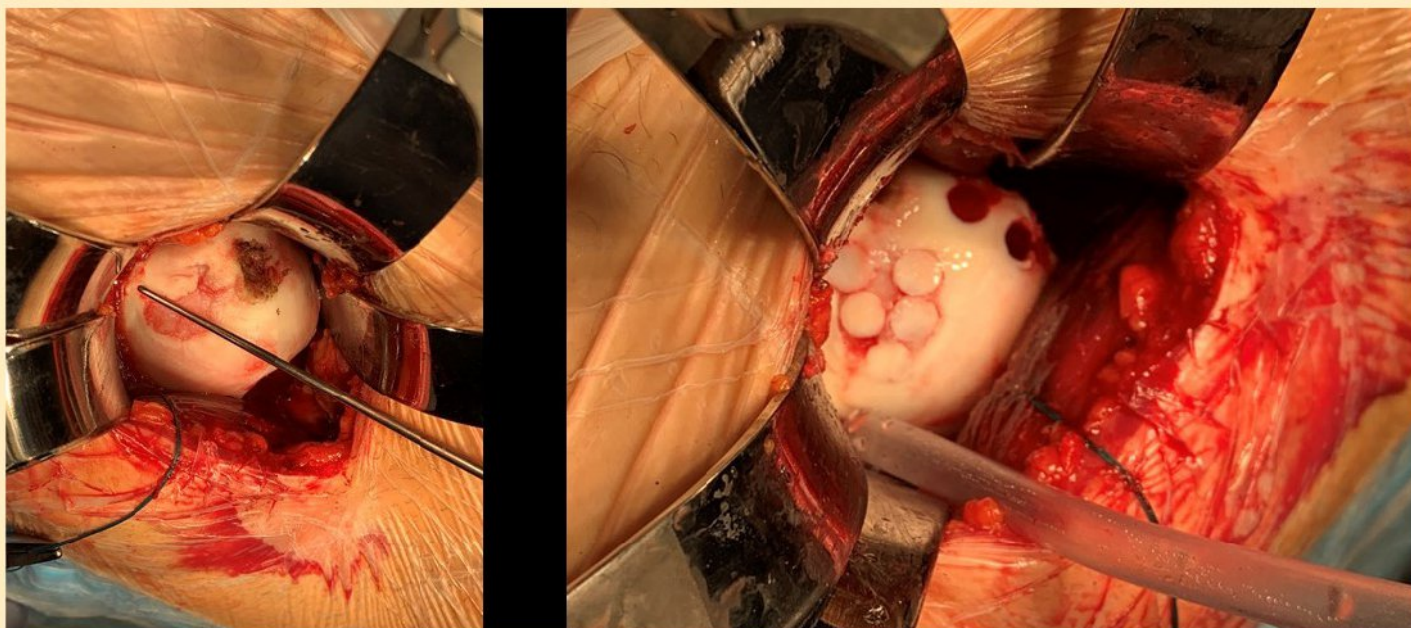
*Radiograph after removal of the material.*

**Case 3: A complex case of varus-producing osteotomy, cartilage transplantation using the mosaicplasty technique and periacetabular osteotomy**

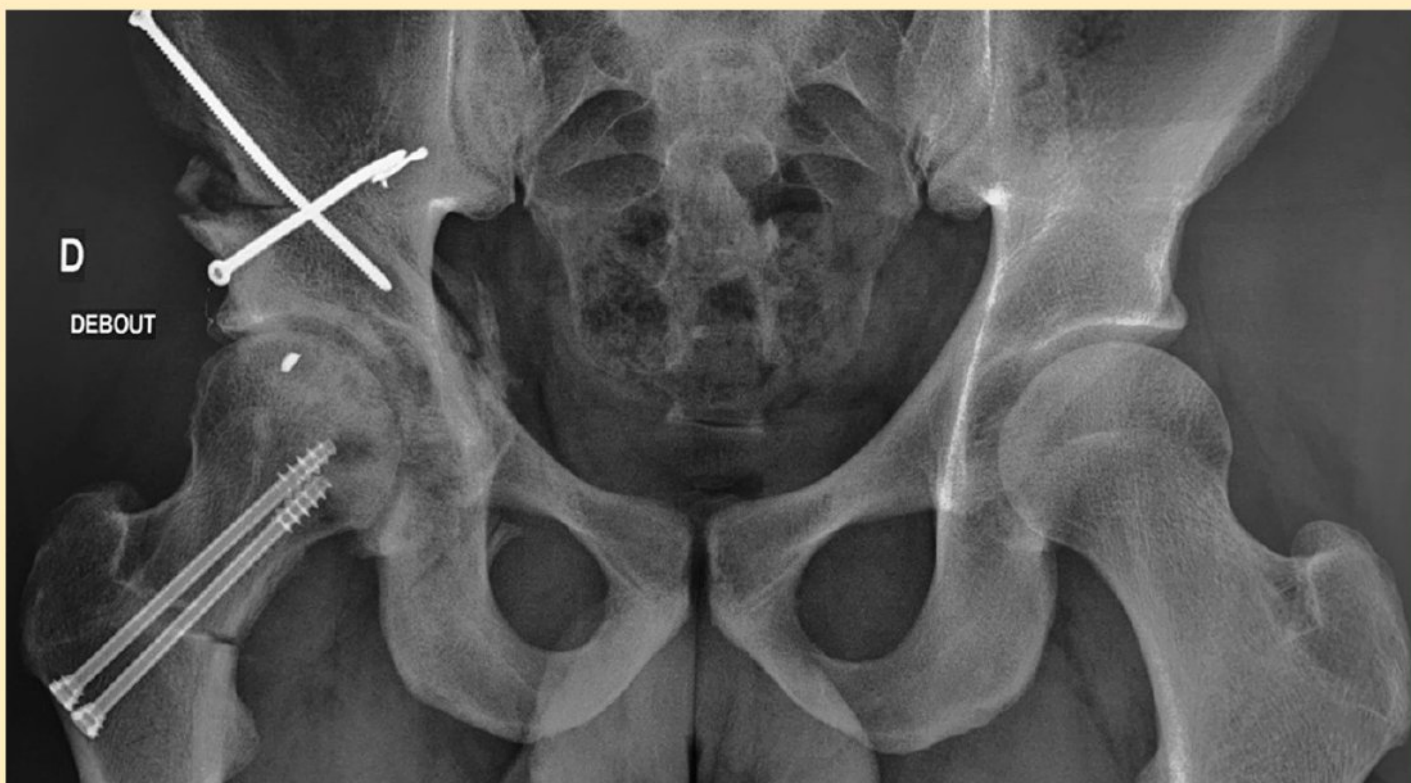


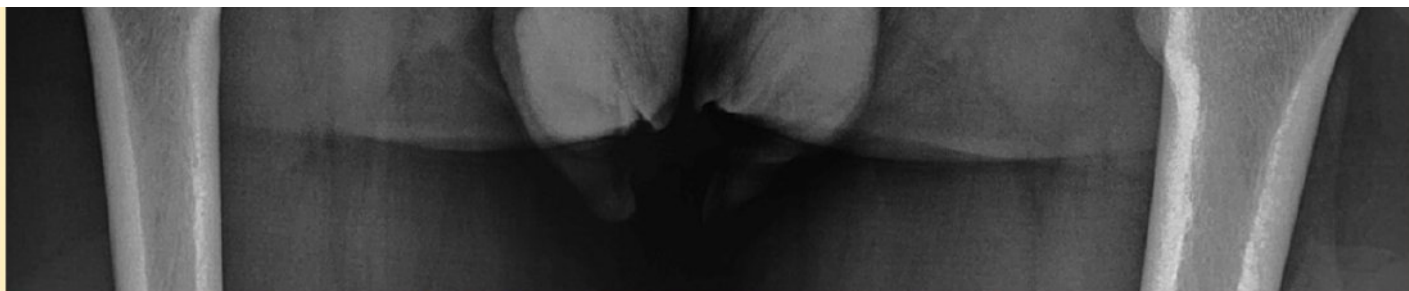
*Standing AP pelvis radiograph. MRI showing coxa valga and femoral head defect. Acetabular dysplasia.*



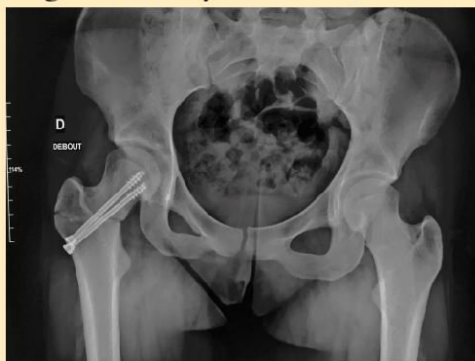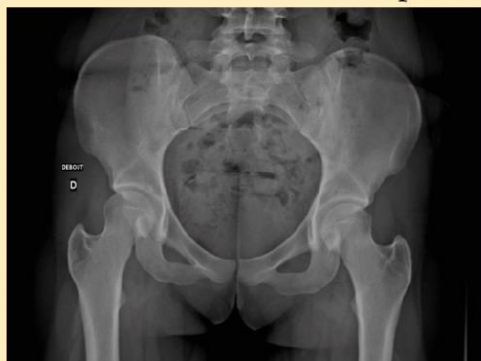*Cartilage transplant on the epiphyseal flap.*



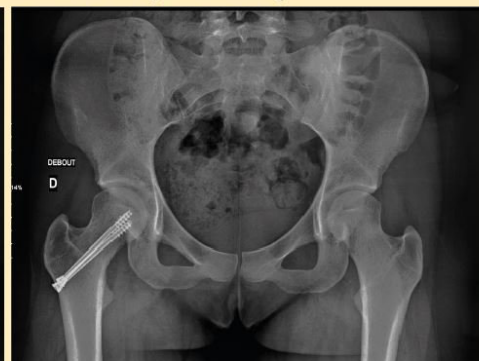

*Postoperative image with full weight-bearing after 6 weeks.*

#### Case 4: Varus-producing osteotomy - Coxa valga with microinstability of the hip.



*Standing AP pelvis radiograph*



*Postoperative radiograph. The osteoclasia line in the greater trochanter is clearly visible.*

## References

1. **Siebenrock, K.A., et al.**, Surgical dislocation of the femoral head for joint debridement and accurate reduction of fractures of the acetabulum. *J Orthop Trauma*, 2002. 16(8): p. 543-52.
2. **Beck, M., et al.**, Femoroacetabular impingement as a factor in the development of nonunion of the femoral neck: a report of three cases. *J Orthop Trauma*, 2004. 18(7): p. 425-30.
3. **Safran, M.R.**, Microinstability of the Hip-Gaining Acceptance. *J Am Acad Orthop Surg*, 2019. 27(1): p. 12-22.
4. **Aalam, M.**, [Implementation of McMurray displacement in adduction osteotomy with AO-instruments (author's transl)]. *Z Orthop Ihre Grenzgeb*, 1977. 115(5): p. 797-42.
5. **Santore, R.F. and R. Bombelli**, Long-term follow-up of the Bombelli experience with osteotomy for osteoarthritis: results at 11 years. *Hip*, 1983: p. 106-28.
6. **Bombelli, R., R.F. Santore, and R. Poss**, Mechanics of the normal and osteoarthritic hip. A new perspective. *Clin Orthop Relat Res*, 1984(182): p. 69-78.
7. **Delbarre, J.C., et al.**, [Total hip arthroplasty after proximal femoral osteotomy: 75 cases with 9-year follow-up]. *Rev Chir Orthop Reparatrice Appar Mot*, 2002. 88(3): p. 24: 56.
8. **Milecki, M., et al.**, [Total hip arthroplasty after previous support proximal femoral osteotomy]. *Chir Narzadow Ruchu Ortop Pol*, 2009. 74(6): p. 334-6.
9. **Ansari, A., et al.**, Varus proximal femoral osteotomy for hip dysplasia in adults. *Hip Int*, 2008. 18(3): p. 200-6.
10. **Ito, H., et al.**, Long-term results of conventional varus half-wedge proximal femoral osteotomy for the treatment of osteonecrosis of the femoral head. *J Bone Joint Surg Br*, 2012. 94(3): p. 308-14.
11. **Olsson, S.S.**, Intratrochanteric osteotomy of the femur with ao-technique for osteoarthritis of the hip joint. *Acta Orthop Scand*, 1974. 45(6): p. 914-25.
12. **Laude, F., E. Sariali, and A. Nogier**, Femoroacetabular impingement treatment using arthroscopy and anterior approach. *Clin Orthop Relat Res*, 2009. 467(3): p. 747-52.
13. **Shigematsu, M. and T. Hotokebuchi**, [Total Hip Arthroplasty after previous proximal femoral osteotomy]. *Clin Calcium*, 2007. 17(6): p. 947-53.
14. **Viamont-Guerra, M.R., et al.**, Promising outcomes of hip mosaicplasty by minimally invasive anterior approach using osteochondral autografts from the ipsilateral femoral head. *Knee Surg Sports Traumatol Arthrosc*, 2019.
15. **Laude, F. and E. Sariali**, [Treatment of FAI via a minimally invasive ventral approach with arthroscopic assistance. Technique and midterm results]. *Orthopade*, 2009. 38(5) p. 419-28.
16. **D'Souza, S.R., et al.**, Proximal femoral osteotomy as the primary operation for young adults who have osteoarthrosis of the hip. *J Bone Joint Surg Am*, 1998. 80(10): p. 1428-38.
17. **Hartigan, D.E., et al.**, Femoral Derotation Osteotomy Technique for Excessive Femoral Anteversion. *Arthrosc Tech*, 2017. 6(4): p. e1405-e1410.
18. **Millis, M.B., R. Poss, and S.B. Murphy**, Osteotomies of the hip in the prevention and treatment of osteoarthritis. *Instr Course Lect*, 1992. 41: p. 145-54.
19. **Buly, R.L., et al.**, Femoral Derotation Osteotomy in Adults for Version Abnormalities. *J Am Acad Orthop Surg*, 2018. 26(19): p. e416-e425.
20. **Ganz, R., K. Klaue, and J. Mast**, [Peri-acetabular reorientation osteotomy]. *Acta Orthop Belg*, 1990. 56(1 Pt B): p. 357-69.
21. **Dewar, D.C., et al.**, The relative contribution of the medial and lateral femoral circumflex arteries to the vascularity of the head and neck of the femur: a quantitative MR based assessment. *Bone Joint J*, 2016. 98-B(12): p. 1582-1588.
22. **Gautier, E., et al.**, Anatomy of the medial femoral circumflex artery and its surgical implications. *J Bone Joint Surg Br*, 2000. 82(5): p. 679-83.
23. **Ganz, R., et al.**, Surgical dislocation of the adult hip a technique with full access to the femoral head and acetabulum without the risk of avascular necrosis. *J Bone Joint Surg Br*, 2001. 83(8): p. 1119-24.

## UPCOMING EVENTS

12.09  
2019

**Lyon Hip Arthroplasty 2019** (<https://mo-journal.com/diary/lyon-hip-arthroplasty-2019-152>)

22.10  
2019

**DKOU - Berlin** (<https://mo-journal.com/diary/dkou-berlin-158>)

08.11  
2019

**ESSKA Speciality Days** (<https://mo-journal.com/diary/esska-speciality-days-145>)

**N°001 - MAY / JUNE 2019**

**SOMMAIRE** (<https://mo-journal.com/journals/view/n001-may-june-2019-497>)

**INTERVIEWS**  
ROB NELISSEN

**ARTICLES**  
Registries and the new EU Medical Device Regulation: Impact on Patient Care, Product Development, Financial Support and Research

**ARTICLES**  
A Multicenter, Multicenter, Controlled, Randomized, Comparative, Prospective, Cohort Study of the Effect of



**THE CONTENT IN MO JOURNAL FOCUSES ON THREE AREAS:**

- teaching and perfecting skills with heavily illustrated articles on surgical techniques
- all of the latest developments in Orthopaedics
- the sharing of knowledge and experience through Interviews with renowned surgeons



► **Read** all issues (<https://mo-journal.com/journals>)

**SUBSCRIBE FROM 70 / YEAR**

The Journal editorial strategy focuses on three areas:  
- teaching with review articles and heavily illustrated surgical techniques  
- news in Orthopaedics focusing on innovations  
- sharing knowledge and experience with the "Interviews"

► **Subscription Form** ([https://mo-journal.com/users/create\\_account](https://mo-journal.com/users/create_account))

► Enter your **redeem code** ([https://mo-journal.com/users/create\\_account](https://mo-journal.com/users/create_account))



This subscription is offered by **Maitrise Orthopédique**

**PLAN DU SITE**

Home (<https://mo-journal.com/>)  
Journals (<https://mo-journal.com/journals>)

Interviews (<https://mo-journal.com/interviews>)  
Congresses (<https://mo-journal.com/congress>)

Videos (<https://mo-journal.com/medias>)  
Events (<https://mo-journal.com/diary>)

News (<https://mo-journal.com/news>)  
Contact (<https://mo-journal.com/contact>)

Industry (<https://mo-journal.com/industry>)  
FAQ (<https://mo-journal.com/faq>)

Legal terms (<https://mo-journal.com/legal-terms>)  
TOS (<https://mo-journal.com/terms-of-sales>)

WARNING : This site is for the medical professionals. The treatments presented only reflect the experience of the authors at the time their article was published in our newspaper. The decision for surgery can only be taken after clinical examination. The techniques published here can not justify any claim from a professional or a patient.

©2018 MO - Journal - All rights reserved - Legal terms (<https://mo-journal.com/legal-terms>)

